



# Diagnostic and Therapeutic Approaches to Thyroid Nodules in Turkey

## Türkiye’de Tiroid Nodüllerine Tanı ve Tedavi Yaklaşımları

<sup>1</sup>Berna İmge AYDOĞAN, <sup>2</sup>Seher DEMİRER\*, <sup>3</sup>Yeşim ERBİL\*\*, <sup>4</sup>Murat Faik ERDOĞAN

Ankara University Faculty of Medicine, Department of Endocrinology and Metabolism, Ankara, Turkey

\*Ankara University Faculty of Medicine, Department of General Surgery, Ankara, Turkey

\*\*İstanbul University Faculty of Medicine, Department of General Surgery, İstanbul, Turkey

### Abstract

**Objective:** This study aimed to evaluate the approaches to thyroid nodules adopted by various specialists and centers in Turkey. **Material and Methods:** The questionnaire designed by Ralf Paschke for International Thyroid Congress (2010) was provided to 400 (264 general surgeons, 58 endocrine surgeons, and 78 endocrinologists) physicians from Turkey. Education and research hospitals (n=110), state hospitals (n=84), university hospitals (n=122), and private hospitals (n=84) were included. An index case was provided and questions regarding diagnostic and therapeutic/follow-up strategies were asked. **Results:** The index case was a 35-year-old man presented with swallowing discomfort. His thyroid-stimulating hormone level was 0.5 mIU/L. Thyroid ultrasonography (US) revealed a 13 mm right nodule (RN) and an 18 mm left nodule (LN). The most frequently queried information by physicians about the case was the result of fine needle aspiration biopsy (FNAB) (38.5%) and scintigraphy+FNAB (25.5%). Routine calcitonin measurement was advised by 33.5% of specialists. US and scintigraphy were detailed as; showed intranodular flow, microcalcification in the solid, and normoactive RN and solid hypoechoic, and hypoactive for the LN. FNAB was recommended by 68.5% of specialists for both nodules. Surgery without FNAB was recommended by 9% (n=36) of specialists, mainly by general surgeons (n=32). Specialists from private hospitals recommended surgical management for benign nodules, more frequently than state and university hospitals (p<0.01). **Conclusion:** Not only invasive and noninvasive diagnostic tests but also the treatment and follow-up strategies varied among general surgeons, endocrine surgeons, and endocrinologists in Turkey. The surgical approach for benign nodules was more frequently preferred in private hospitals.

**Keywords:** Thyroid nodule; fine-needle aspiration biopsy; thyroid ultrasonography; surgery

### Özet

**Amaç:** Bu çalışmada, Türkiye’de farklı merkez ve uzmanlık alanlarından hekimlerin tiroid nodüllerine yaklaşımlarının değerlendirilmesi amaçlanmıştır. **Gereç ve Yöntemler:** Uluslararası Tiroid Kongresi (2010) için Ralf Paschke tarafından tasarlanan anket, Türkiye’de 400 (264 genel cerrah, 58 endokrin cerrah ve 78 endokrinolog) uzman hekime uygulandı. Eğitim ve araştırma hastaneleri (n=110), devlet hastaneleri (n=84), üniversite hastaneleri (n=122) ve özel hastaneler (n=84) dâhil edildi. İndeks bir hasta verildi ve tanı, tedavi/takip stratejilerine ilişkin sorular soruldu. **Bulgular:** İndeks olgu 35 yaşında, yutma güçlüğü ile başvuran erkek hastaydı. Tiroid stimüle edici hormon (TSH) düzeyi 0.5 mIU/mL idi. Tiroid ultrasonografi (USG)’sinde sağda 13 mm ve solda 18 mm nodül mevcuttu. Uzmanların hasta hakkında en sık öğrenmek istediği bilgiler, ince iğne aspirasyon biyopsisi sonucu (İİAB) (%38,5) ve sintigrafi+İİAB (%25,5) sonuçlarıydı. Rutin kalsitonin ölçümü uzmanların %33,5’i tarafından önerildi. USG ve sintigrafi; sağ normoaktif solid nodülde mikrokalsifikasyon ve intranodüler kanlanma ve sol hipoaktif nodülde hipoekoje-nite olarak detaylandırıldı. Her 2 nodül için İİAB, uzmanların %68,5’i tarafından önerildi. İİAB yapılmadan cerrahi, uzman hekimlerin %9’u (n=36) tarafından ve çoğunlukla genel cerrahlarca (n=32) önerildi. Özel hastanelerden uzmanlar, benign nodüller için cerrahi yaklaşımı, devlet ve üniversite hastanelerine göre daha sık önerdi (p<0.01). **Sonuç:** Türkiye’de hem girişimsel/girişimsel olmayan tanısal testler hem de tedavi/takip stratejileri genel cerrahlar, endokrin cerrahlar ve endokrinologlar arasında değişkenlik göstermektedir. Benign nodüllerin tedavisinde cerrahi yaklaşım özel hastanelerde daha sık tercih edilmektedir.

**Anahtar kelimeler:** Tiroid nodülü; ince iğne aspirasyon biyopsisi; tiroid ultrasonografisi; cerrahi

**Address for Correspondence:** Berna İmge AYDOĞAN, Ankara University Faculty of Medicine, Department of Endocrinology and Metabolism, Ankara, Turkey  
**Phone:** +90 312 508 21 00 **E-mail:** imgehalici@gmail.com

Peer review under responsibility of Turkish Journal of Endocrinology and Metabolism.

**Received:** 29 Sep 2019 **Received in revised form:** 02 Jan 2020 **Accepted:** 23 Jan 2020 **Available online:** 05 Feb 2020

1308-9846 / © Copyright 2020 by Society of Endocrinology and Metabolism of Turkey.

Publication and hosting by Türkiye Klinikleri.

This is an open access article under the CC BY-NC-SA license (<https://creativecommons.org/licenses/by-nc-sa/4.0/>)

## Introduction

Thyroid nodules (TNs) are observed frequently, and the prevalence of palpable nodules reaches 1% in men and 5% in women in iodine-sufficient regions of the world (1,2). The detection of TNs has become more common with the widespread use of thyroid ultrasonography (US) and the prevalence is up to 68% using high-frequency (13 MHz) US examination (3). The differential diagnosis of thyroid malignancy and determination of functional status are essential in TN management. The frequency of malignancy among TNs is 5-15% (4). The diagnostic procedures include the evaluation of thyroid-stimulating hormone (TSH), thyroid autoantibodies, calcitonin, US,  $I^{123}$ , and Tc-99m pertechnetate thyroid scintigraphy. Thyroid US followed by fine-needle aspiration biopsy (FNAB) is recommended for evaluating selected nodules (5). However, the overdiagnosis and overtreatment of TNs are topical issues (6).

The previous data from Europe and the United States demonstrated discrepancies among endocrinologists, general surgeons, and endocrine surgeons in the diagnostic and therapeutic approaches to TNs (7-10). The American Association of Clinical Endocrinologists, Associazione Medici Endocrinologi, and European Thyroid Association medical (AACE/AME/ETA) guidelines 2010 and American Thyroid Association (ATA) guideline 2009 addressed several issues on the management of TNs (4,11). However, surveys conducted after the publication of guidelines showed that there were controversies among physicians from different specialties and centers, despite the presence of updated recommendations (12).

This study aimed to evaluate the management strategies of TNs among different specialties and medical centers in Turkey.

## Material and Methods

### Structure of the Questionnaire

This cross-sectional study was conducted in 2010. The questionnaire was adapted from that designed for International Thyroid Congress 2010 by Ralf Paschke with permission. A total of 400 physicians from different dis-

ciplines and institutions and 264 general surgeons (58 endocrine surgeons and 78 endocrinologists) answered the questions. Institutions were state hospitals (n=194), university hospitals (n=122), and private hospitals (n=84). The results were interpreted considering the recommendations of revised ATA 2009 and AACE/AME/ETA 2010 guidelines.

The questionnaire was based on an index case: a 35-year-old man admitted to the clinic with swallowing discomfort. Thyroid US revealed a 13 mm right nodule (RN) and an 18 mm left nodule (LN). The TSH level was 0.5 mIU/L (reference range [RR]=0.5-5.5 mIU/L). The participants were asked to choose only one option for all questions.

In the first part of the survey, the questions were based on the initial diagnostic tests used for the evaluation of TNs. In the second part, the results of more detailed thyroid US and scintigraphy were provided. In the first scenario, the right solid nodule had intranodular blood flow and microcalcification on power Doppler and B-mode US, respectively. Tc-99m pertechnetate thyroid scintigraphy showed that RN was normoactive. The LN was solid and hypoechoic on US and hypoactive on scintigraphy. The choice of FNAB for each nodule or surgery was asked.

The second scenario in this section was about a RN with iso-hyperechogenicity and LN with mixed cystic-solid texture on US. The choice of FNAB for each nodule or surgery was asked again.

In the final part of the questionnaire, follow-up and treatment options were questioned. The approach to benign nodules and the estimated risk of malignancy in nodules with indeterminate cytology were asked to physicians. Informed consent was obtained from each participant.

### Statistical Analysis

Statistical analyses were performed using SPSS for Windows 11.5 (IBM Corp, NY, USA). The chi-square or Fisher's exact test was performed to compare diagnostic and therapeutic approaches of physicians from different specialties and medical centers. A *p*-value of <0.05 was considered statistically significant.

## Results

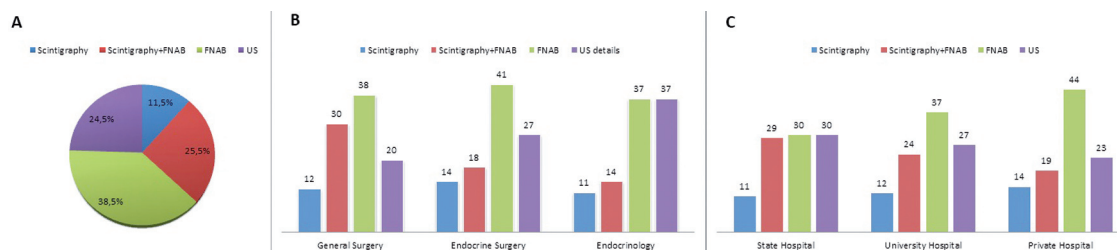
The case was presented as follows: a 35-year-old man admitted to the clinic with swallowing discomfort. Thyroid US revealed a 13 mm RN and 18 mm LN. The TSH level was 0.5 mIU/L (RR: 0.5-5.5 mIU/L).

## Diagnostic Procedures

In the first part of the questionnaire, FNAB was used by 38.5% of responders (n=154), FNAB and scintigraphy by 25.5% (n=102), US by 24.5% (n=98), and scintigraphy by 11.5% (n=46) (Figure 1A). Among endocrinologists, US (37%) and scintigraphy (37%) were used at an equal rate, whereas general surgeons (38%) and endocrine surgeons (41%) most commonly used FNAB alone (Figure 1B). Scintigraphy followed by FNAB was more frequently recommended by general surgeons (n=79) than endocrinologists (n=14) (30% versus 14%,  $p=0.04$ ), whereas no statistically significant difference was observed between disciplines regarding the selection of other initial diagnostic procedures. In all medical centers, FNAB was the most preferred initial diagnostic method and no difference regarding the selection of FNAB was observed between private and university hospitals ( $p=0.06$ ) (Figure 1C). In private hospitals, FNAB was more frequently preferred as an initial approach than state hospitals ( $p=0.04$ ).

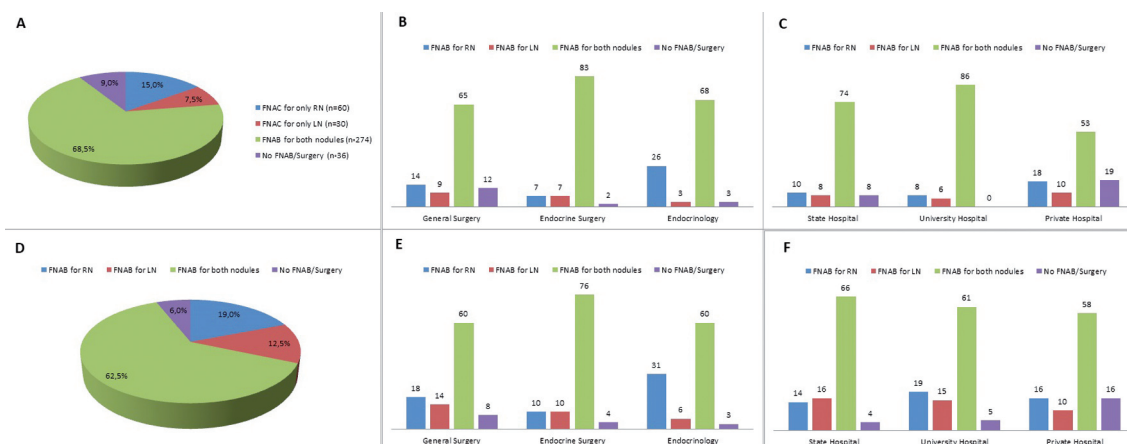
The routine calcitonin measurement was not recommended by 66.5% (n=266) of physicians. The calcitonin measurement was more frequently used by endocrinologists than general surgeons (54% versus 33%,  $p=0.08$ ) and endocrine surgeons (54% versus 14%,  $p=0.01$ ).

In the second part of the questionnaire, the selection of invasive diagnostic methods was asked. In the first scenario, US and scintigraphy results were summarized as follows: "Right solid nodule had intranodular blood flow and microcalcification on power Doppler and B-mode US, respectively. Tc-99m pertechnetate thyroid scintigraphy showed that RN was normoactive. LN was solid and hypoechoic on US and hypoactive on scintigraphy." In the entire group, 68.5% (n=274) of responders suggested FNAB for two nodules, 15% (n=60) for RN, and 7.5% (n=30) for LN (Figure 2A). Surgery without FNAB was recommended by 9% (n=36) of clinicians. FNAB was the most preferred approach among endocrinologists (68%), general surgeons (65%), and endocrine surgeons (83%) (Figure 2B). FNAB was more commonly recommended by endocrinologists for only RN than general surgeons and endocrine surgeons (26% versus 14%,  $p=0.01$  and 26% versus 7%,  $p=0.01$ , respectively), whereas the recommendation of FNAB for only LN was not different among the disciplines. Endocrine surgeons more commonly recommended FNAB for both nodules (83%) than general surgeons (65%) and endocrinologists (68%) ( $p=0.02$ ). Surgery without FNAB was more frequently recommended by general surgeons than endocrinologists (12% versus 3%,  $p=0.01$ ) and endocrine surgeons (12% versus 3%,  $p=0.03$ ) (Figure 2B). Physicians from private hospitals more frequently preferred surgery (19%) than those from state hospitals (8%,  $p<0.01$ ). None of the specialists from university hospitals preferred



**Figure 1:** The index case was a 35-year-old male patient. Thyroid US revealed a 13 mm right nodule (RN) and an 18 mm left nodule (LN). The TSH level was 0.5 mIU/L [Reference range (RR): 0.5-5.5 mIU/L].

The diagnostic evaluation of this patient was questioned (A). Diagnostic approach to the patient according to medical disciplines (B). Diagnostic approach to the patient according to medical centers (C).



**Figure 2:** In the first scenario; the right-solid nodule had intranodular blood flow and microcalcification on the power Doppler and B-mode US, respectively. Tc-99m pertechnetate thyroid scintigraphy showed that the right nodule (RN) was normoactive. The left nodule (LN) was solid and hypoechoic on US and hypoactive on scintigraphy. Approach to the nodules in the first scenario among all physicians (A), according to medical disciplines (B), and medical centers (C).

The second scenario of US was given as follows; "RN showed iso-hyperechogenicity and LN showed mixed cystic-solid texture". Choice of management was asked again. Approach to the nodules in the second scenario among all physicians (D), according to medical disciplines (E), and medical centers (F).

surgery for this scenario. On the other hand, FNAB was the most preferred method for both nodules in university (86%), state (74%), and private (53%) hospitals (Figure 2C).

The second scenario of US was given as follows: "RN showed iso-hyperechogenicity and LN showed mixed cystic-solid texture". The choice of management was asked again. FNAB was selected for both nodules by 62.5% (n=250) physicians (Figure 2D). FNAB was more commonly recommended for only RN by endocrinologists than general surgeons and endocrine surgeons (31% versus 18% and 10%, respectively,  $p=0.01$ ). Surgery without FNAB was more frequently recommended by general surgeons than endocrinologists and endocrine surgeons (8% versus 3% and 8% versus 4%, respectively,  $p=0.009$ ) (Figure 2E). Surgery was more frequently recommended in a private hospital setting than university and state hospitals (16% versus 5% and 4%, respectively,  $p=0.002$ ) (Figure 2F).

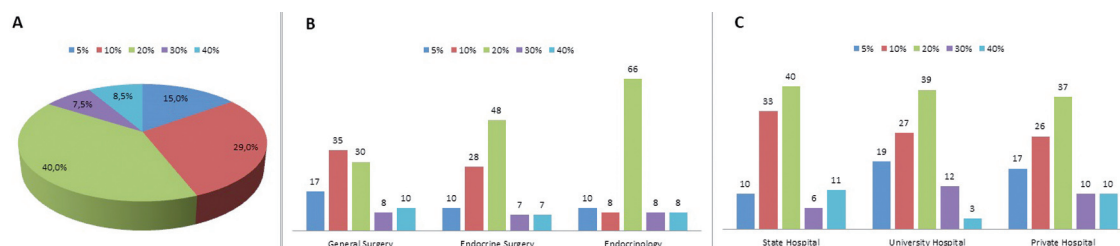
In the last part of the study, the results of FNAB according to the "Bethesda system for reporting thyroid cytopathology and revised ATA 2009 guideline" for both nodules were given as follows: "indeterminate for 18 mm LN and benign for 13 mm RN". The risk of

malignancy in nodules with indeterminate FNAB result was asked to physicians. The given risks were 5%, 10%, 20%, 30%, and 40% by 15%, 29%, 40%, 7.5%, and 8.5% of physicians, respectively (Figure 3A). The most frequently given risk was 20% in all disciplines and medical centers (Figure 3B-3C).

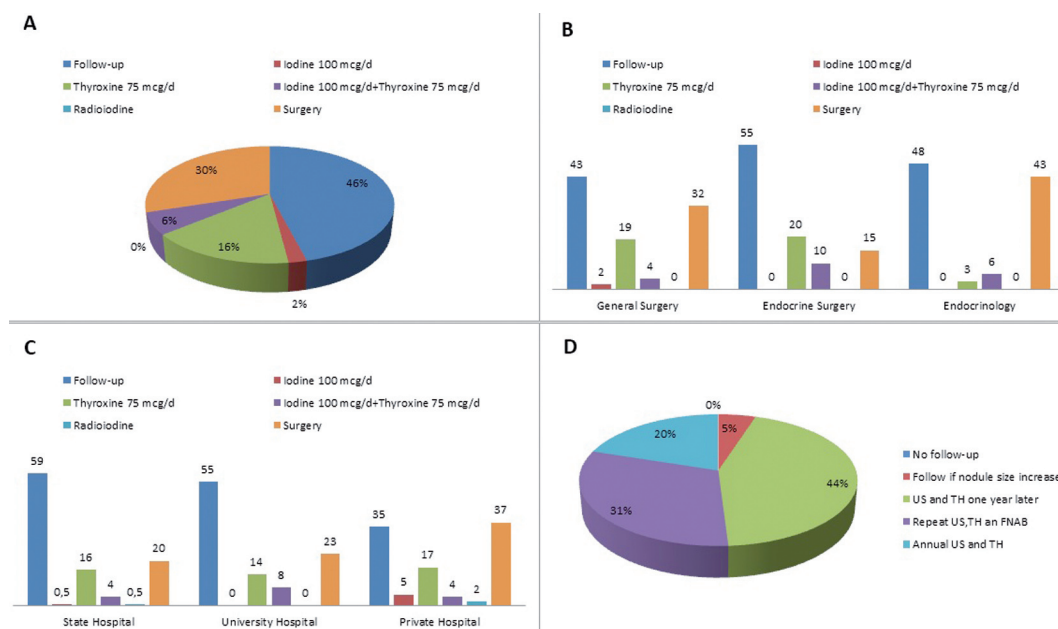
### Follow-up and Treatment

The subsequent question was "which follow-up strategy you would recommend for the patient if both nodules were benign by FNAB, the thyroid volume was 30 mL and after two further years there were two further benign nodules?". Follow-up was the most preferred strategy (46%, n=182) (Figure 4A). Surgery was more frequently recommended by endocrinologists than endocrine surgeons (43% versus 15%,  $p=0.01$ ; Figure 4B). Levothyroxine or levothyroxine plus iodine treatments were more frequently preferred by general surgeons and endocrine surgeons than endocrinologists (23% and 30% versus 9%,  $p<0.001$ ) (Figure 4B). Surgery was recommended by 37% of physicians from private medical centers, 23% from university, and 20% from state hospitals ( $p<0.01$ ; Figure 4C).





**Figure 3:** The given risk of malignancy of nodules with indeterminate cytology results (A), according to medical disciplines (B), and medical centers (C).



**Figure 4:** Management of benign nodules in whole group (A), according to medical disciplines (B), and medical centers (C). Follow-up strategies in benign nodules (D).

The last question was the most preferred follow-up strategy for this patient. The evaluation of US and thyroid hormones after one year and further follow-up depending on results were selected by 44% (n=176) of physicians (Figure 4D).

## Discussion

This survey evaluated diagnostic and therapeutic approaches to TNs among thyroid specialists from different disciplines and centers in Turkey. Our results showed that controversies existed among disciplines despite the recommendations of guidelines. In addition, differences in follow-up and treatment strategies of medical centers were documented.

Since the 1980s, investigators focused on the management attitudes and practices of physicians from different centers and disciplines regarding thyroid nodularity (7,9,10,13-15). The first international survey regarding the approach to "a small TN in a 35-year-old woman" was conducted by Baldet et al. in 1989. After 10 years of this survey, Bennedbaek conducted a similar survey among 110 clinical members of the European Thyroid Association, and subsequently, the same survey was conducted among 142 North American physicians (ATA members) including endocrinologists, general surgeons, and nuclear medicine specialists (7,13). In 2007, the questionnaire was answered by 122 endocrinologists and

48 endocrine surgeons from Australia (9). When Australian clinicians and ETA and ATA members were compared, the use of US was significantly infrequent among ATA members. Scintigraphy regardless of thyroid function was more frequently recommended in the European survey than North American and Australian surveys (9). The German Society of Endocrinology provided the same questionnaire among 50 participants including endocrinologists and nuclear medicine specialists in 2003 (10). The use of US as an initial procedure was more frequent, but FNAB was rare in Germany compared with former surveys conducted in Europe and North America (7,9,10,13).

Previous data demonstrated that not only diagnostic tests but also follow-up and therapeutic strategies for benign TNs varied among physicians and medical disciplines. Thyroxine treatment was recommended by only 7.6% of Australian specialists, whereas this rate was 33% and 38% among ATA and ETA members, respectively (7,9,13). The preferred strategy in the management of benign TN was rarely surgery by ATA members (0.7%) (13). However, Australian physicians and ETA members equally (approximately 21%) and more frequently recommended surgery for benign nodules (7,9). In an Australian survey, the surgical approach was significantly and more frequently recommended by surgeons than endocrinologists (60% versus 22%) (9).

The results of these surveys pointed out the need for consensus on TN management (4). The initial "American Thyroid Association (ATA) guideline for patients with TNs and differentiated thyroid cancer" was published in 2006 (16). The revised guideline of ATA was published in 2009 (4). The major questions addressed by authors were the indications of imaging techniques (US and scintigraphy), laboratory tests, the role of FNAB, medical therapy for benign nodules, and long-term follow-up strategies. The AACE/AME/ETA guidelines for clinical practice for the diagnosis and management of TN were published in 2010 (17). ATA 2009 and AACE/AME/ETA guidelines recommend the measurement of TSH level initially and performing a radionuclide thyroid scan if the TSH level was subnormal for TN management (4). Thyroid US was recommended for

all patients with known or suspected TN. If a hyperfunctioning nodule was observed on nuclear imaging, the cytologic evaluation was not recommended, as these nodules are rarely malignant (18). Although our survey was conducted after the publication of revised ATA 2009 and AACE/AME/ETA guidelines, the initial approach to TN varied broadly among clinicians from the same or different disciplines. Ultrasonography alone and FNAB without US were equally recommended by endocrinologists, whereas the initial approach to nodule was commonly FNAB followed by US among all experts. No difference was observed regarding the selection of FNAB as an initial approach between private and university hospitals. However, FNAB was more frequently preferred by physicians from private hospitals than that from state hospitals.

The use of routine calcitonin measurement in TN management is controversial. The ATA 2009 guidelines do not recommend either for or against the routine calcitonin measurement (4). On the other hand, AACE/EMA/ETA guidelines state that serum calcitonin testing may be useful in the initial evaluation of TNs with moderate-quality evidence (17). The surveys from Europe reported that 20-40% of specialists requested routine calcitonin measurement (7,15). A previous survey was conducted in Turkey between 2014 and 2015 among general surgeons (12). The survey results demonstrated that routine calcitonin measurement was recommended by only 8.4% of participants. Similar to European surveys, 33.5% of participants recommended routine calcitonin testing in our study. Endocrinologists more frequently recommended routine measurement than surgeons (7,9).

In ATA 2009 guideline, the indications of FNAB were as follows: a nodule of >5 mm in a patient with a high-risk history of thyroid malignancy, a hypoechoic nodule of >10 mm, an iso- or hyperechoic nodule of ≥10-15 mm, a spongiform nodule of ≥20 mm, a mixed cystic-solid nodule without suspicious US features of ≥20 mm, and ≥15-20 mm if any suspicious US features were present (4). The AACE/AME/ETA thyroid nodule 2010 guidelines recommend FNAB for nodules larger than 10 mm and smaller than 10 mm if had a suspicious history or US find-

ings. In our first scenario, FNAB was indicated for both nodules according to ATA 2009 and AACE/AME/ETA guidelines; RN was a normoactive, 13 mm solid nodule with suspicious US features (intranodular blood flow and microcalcification), and LN was 18 mm hypoechoic and hypoactive. The biopsy of both nodules was recommended by 65% of general surgeons, 83% of endocrine surgeons, and 68% of endocrinologists. A significant difference was observed regarding the choice of surgery without FNAB among disciplines. General surgeons more commonly requested surgery as a diagnostic procedure than other disciplines. In addition, surgery was more frequently recommended by physicians from private hospitals than those from state and university hospitals. In the second scenario, RN showed isohyperechogenicity and LN showed mixed cystic-solid texture. According to ATA 2009, FNAB was optional for RN but was not indicated for LN. FNAB was the most frequently chosen option in all disciplines for both nodules. Diagnostic surgery was more frequently recommended by general surgeons and physicians from private hospitals.

In the last part of the questionnaire, the risk of malignancy in nodules reported as "indeterminate" by FNAB was asked to participants. Indeterminate cytology included "follicular or Hurthle cell neoplasm" and atypia/follicular lesion of undetermined significance (AUS/FLUS) Bethesda categories (19). Follicular neoplasm and/or Hurthle cell neoplasms were reported to have a 20-30% AUS/FLUS lesions and 5-10% risk of malignancy (4,20). In our survey, 40% of physicians gave a 20% risk of malignancy for indeterminate nodules. General and endocrine surgeons provided lower risks than endocrinologists.

According to ATA 2009 and AACE/AME/ETA 2010 guidelines, the recommended strategy in the management of benign nodules was a follow-up, as false negative results were low (4,21). Serial follow-up with clinical US examination and TSH measurement in 6 to 18 months were recommended in AACE/AME/ETA 2010 guidelines. Long-term levothyroxine suppressive therapy was not recommended because of regrowth after the cessation of treatment (4,17). In our survey, follow-up was most commonly recom-

mended for the management of benign nodules and the evaluation of US and thyroid hormones one year later was the most preferred follow-up strategy; further, follow-up depended on the results. Surgery was recommended by 32% of physicians. Endocrinologists and physicians from private hospitals advised surgery. Our results were consistent with the previous survey from Turkey that showed discrepancies in the evaluation and treatment of TNs among general surgeons (12).

In conclusion, the approach to TNs is controversial among different disciplines and institutions in Turkey despite the recommendations of guidelines. Not only invasive/noninvasive diagnostic tests but also the treatment and follow-up strategies varied among general surgeons, endocrine surgeons, and endocrinologists. In addition, the private hospital setting was associated with an increase in the frequency of surgery.

### Source of Finance

During this study, no financial or spiritual support was received neither from any pharmaceutical company that has a direct connection with the research subject, nor from a company that provides or produces medical instruments and materials which may negatively affect the evaluation process of this study.

### Conflict of Interest

No conflicts of interest between the authors and / or family members of the scientific and medical committee members or members of the potential conflicts of interest, counseling, expertise, working conditions, share holding and similar situations in any firm.

### Authorship Contributions

Idea/Concept: Murat Faik Erdoğan, Yeşim Erbil, Seher Demirel; Design: Murat Faik Erdoğan, Seher Demirel, Yeşim Erbil; Control/Supervision: Berna İmge Aydoğan, Murat Faik Erdoğan, Yeşim Erbil; Data Collection and/or Processing: Murat Faik Erdoğan, Berna İmge Aydoğan, Seher Demirel, Yeşim Erbil; Analysis and/or Interpretation: Berna İmge Aydoğan, Murat Faik Erdoğan, Seher Demirel, Yeşim Erbil; Literature Review: Berna İmge Aydoğan,

Murat Faik Erdoğan; Writing the Article: Berna İmge Aydoğan, Murat Faik Erdoğan, Seher Demirer; Critical Review: Berna İmge Aydoğan, Murat Faik Erdoğan; References and Findings: Berna İmge Aydoğan, Murat Faik Erdoğan, Seher Demirer, Yeşim Erbil; Materials: Yeşim Erbil, Murat Faik Erdoğan, Seher Demirer.

## References

1. Tunbridge WM, Evered DC, Hall R, Appleton D, Brewis M, Clark F, Evans JG, Young E, Bird T, Smith PA. The spectrum of thyroid disease in a community: the Whickham survey. *Clin Endocrinol (Oxf)*. 1977;7:481-493. [\[Crossref\]](#) [\[PubMed\]](#)
2. Vander JB, Gaston EA, Dawber TR. The significance of nontoxic thyroid nodules. Final report of a 15-year study of the incidence of thyroid malignancy. *Ann Intern Med*. 1968;69:537-540. [\[Crossref\]](#) [\[PubMed\]](#)
3. Guth S, Theune U, Aberle J, Galach A, Bamberger CM. Very high prevalence of thyroid nodules detected by high frequency (13 MHz) ultrasound examination. *Eur J Clin Invest*. 2009;39:699-706. [\[Crossref\]](#) [\[PubMed\]](#)
4. Cooper DS, Doherty GM, Haugen BR, Kloos RT, Lee SL, Mandel SJ, Mazzaferri EL, McIver B, Pacini F, Schlumberger M, Sherman SI, Steward DL, Tuttle RM; American Thyroid Association (ATA) Guidelines Taskforce on Thyroid Nodules and Differentiated Thyroid Cancer. Revised American Thyroid Association management guidelines for patients with thyroid nodules and differentiated thyroid cancer. *Thyroid*. 2009;19:1167-1214. [\[Crossref\]](#) [\[PubMed\]](#)
5. Haugen BR, Alexander EK, Bible KC, Doherty GM, Mandel SJ, Nikiforov YE, Pacini F, Randolph GW, Sawka AM, Schlumberger M, Schuff KG, Sherman SI, Sosa JA, Steward DL, Tuttle RM, Wartofsky L. 2015 American Thyroid Association Management Guidelines for Adult Patients with Thyroid Nodules and Differentiated Thyroid Cancer: The American Thyroid Association Guidelines Task Force on Thyroid Nodules and Differentiated Thyroid Cancer. *Thyroid*. 2016;26:1-133. [\[Crossref\]](#) [\[PubMed\]](#) [\[PMC\]](#)
6. Ahn HS, Kim HJ, Welch HG. Korea's thyroid-cancer "epidemic"--screening and overdiagnosis. *N Engl J Med*. 2014;371:1765-1767. [\[Crossref\]](#) [\[PubMed\]](#)
7. Bennedbaek FN, Perrild H, Hegedüs L. Diagnosis and treatment of the solitary thyroid nodule. Results of a European survey. *Clin Endocrinol (Oxf)*. 1999;50:357-363. [\[Crossref\]](#) [\[PubMed\]](#)
8. Burch HB, Burman KD, Cooper DS, Hennessey JV, Vietor NO. A 2015 survey of clinical practice patterns in the management of thyroid nodules. *J Clin Endocrinol Metab*. 2016;101:2853-2862. [\[Crossref\]](#) [\[PubMed\]](#)
9. Walsh JP, Ryan SA, Lisewski D, Alhamoudi MZ, Brown S, Bennedbaek FN, Hegedüs L. Differences between endocrinologists and endocrine surgeons in management of the solitary thyroid nodule. *Clin Endocrinol (Oxf)*. 2007;66:844-853. [\[Crossref\]](#) [\[PubMed\]](#)
10. Führer D, Mügge C, Paschke R. Questionnaire on management of nodular thyroid disease (Annual Meeting of the Thyroid Section of the German Society of Endocrinology 2003). *Exp Clin Endocrinol Diabetes*. 2005;113:152-159. [\[Crossref\]](#) [\[PubMed\]](#)
11. Cobin RH, Gharib H, Bergman DA, Clark OH, Cooper DS, Daniels GH, Dickey RA, Duick DS, Garber JR, Hay ID, Kukora JS, Lando HM, Schorr AB, Zeiger MA; Thyroid Carcinoma Task Force. AACE/AAES medical/surgical guidelines for clinical practice: management of thyroid carcinoma. American Association of Clinical Endocrinologists. American College of Endocrinology. *Endocr Pract*. 2001;7:202-220. [\[Crossref\]](#) [\[PubMed\]](#)
12. Isik A, Firat D, Yilmaz I, Peker K, Idiz O, Yilmaz B, Demiryilmaz I, Celebi F. A survey of current approaches to thyroid nodules and thyroid operations. *Int J Surg*. 2018;54:100-104. [\[Crossref\]](#) [\[PubMed\]](#)
13. Bennedbaek FN, Hegedüs L. Management of the solitary thyroid nodule: results of a North American survey. *J Clin Endocrinol Metab*. 2000;85:2493-2498. [\[Crossref\]](#) [\[PubMed\]](#)
14. Massol J, Pazart L, Aho S, Strauch G, Leclerc J, Durieux P. Management of the thyroid nodule. Preliminary results of a practice survey of 685 general practitioners and specialists. *Ann Endocrinol (Paris)*. 1993;54:220-225. [\[PubMed\]](#)
15. Baldet L, Manderscheid JC, Glinioer D, Jaffiol C, Coste-Seignover B, Percheron C. The management of differentiated thyroid cancer in Europe in 1988. Results of an international survey. *Acta Endocrinol (Copenh)*. 1989;120:547-558. [\[Crossref\]](#) [\[PubMed\]](#)
16. Cooper DS, Doherty GM, Haugen BR, Kloos RT, Lee SL, Mandel SJ, Mazzaferri EL, McIver B, Sherman SI, Tuttle RM; American Thyroid Association Guidelines Taskforce. Management guidelines for patients with thyroid nodules and differentiated thyroid cancer. *Thyroid*. 2006;16:109-142. [\[Crossref\]](#) [\[PubMed\]](#)
17. Gharib H, Papini E, Paschke R, Duick DS, Valcavi R, Hegedüs L, Vitti P; AACE/AME/ETA Task Force on Thyroid Nodules. American Association of Clinical Endocrinologists, Associazione Medici Endocrinologi, and European Thyroid Association Medical guidelines for clinical practice for the diagnosis and management of thyroid nodules: executive summary of recommendations. *Endocr Pract*. 2010;16:468-475. [\[Crossref\]](#) [\[PubMed\]](#)
18. Boelaert K, Horacek J, Holder RL, Watkinson JC, Sheppard MC, Franklyn JA. Serum thyrotropin concentration as a novel predictor of malignancy in thyroid nodules investigated by fine-needle aspiration. *J Clin Endocrinol Metab*. 2006;91:4295-4301. [\[Crossref\]](#) [\[PubMed\]](#)
19. Cibas ES, Ali SZ; NCI Thyroid FNA State of the Science Conference. The Bethesda System For Reporting Thyroid Cytopathology. *Am J Clin Pathol*. 2009;132:658-665. [\[Crossref\]](#) [\[PubMed\]](#)
20. Baloch ZW, LiVolsi VA, Asa SL, Rosai J, Merino MJ, Randolph G, Vielh P, DeMay RM, Sidawy MK, Frable WJ. Diagnostic terminology and morphologic criteria for cytologic diagnosis of thyroid lesions: a synopsis of the National Cancer Institute Thyroid Fine-Needle Aspiration State of the Science Conference. *Diagn Cytopathol*. 2008;36:425-437. [\[Crossref\]](#) [\[PubMed\]](#)
21. Carmeci C, Jeffrey RB, McDougall IR, Nowels KW, Weigel RJ. Ultrasound-guided fine-needle aspiration biopsy of thyroid masses. *Thyroid*. 1998;8:283-289. [\[PubMed\]](#)