



# Steroid Secreting Dedifferentiated Liposarcoma: A Unique Presentation

## Steroid Salgılayan Dediferansiye Liposarkom: Özgün Bir Sunum

Lucas Ribeiro dos Santos, Márcio Luis Duarte\*, José Viana Lima Júnior\*\*

Clinic of Endocrinology and Metabology at Medical Sciences Faculty of Santos, São Paulo, Brazil

\*Radiologist of Webimagem. Avenida Marquês de São Vicente, 446, São Paulo, Brazil

\*\*Clinic of Endocrinology and metabology at Medical Sciences Faculty of Santa Casa de Misericórdia de São Paulo, São Paulo, Brazil

### Abstract

Adrenal tumors are cancerous or non-cancerous growths on the adrenal glands. It can originate from the cortex or the medulla, and may or may not have the capacity to secrete hormones. We report a case of a 76-year-old man who was diagnosed with an adrenal mass during abdominal pain investigation. His biochemical profile and magnetic resonance images are compatible with adrenocortical carcinoma, while the pathology reports are compatible with liposarcoma. So far, to the best of our knowledge, there is no report on steroid-secreting tumors.

**Keywords:** Adrenal cancer; dedifferentiated liposarcoma; Cushing syndrome

### Özet

Adrenal tümörler, adrenal bezlerdeki kanseröz veya non-kanseröz büyümelelerdir. Korteks veya medulladan kaynaklanabilirler ve hormon salgılama kapasitesine sahip olabilir veya olmayabilirler. Burada, karın ağrısı muayenesi sırasında adrenal kitle tanısı konan 76 yaşında bir erkek olgu sunduk. Olgunun biyokimyasal profili ve manyetik rezonans görüntüleri adrenokortikal karsinom ile patoloji raporları liposarkom ile uyumlu idi. Bildiğimiz kadarıyla, şimdiye kadar steroid salgılayan tümörler hakkında bir olgu sunumu bulunmamaktadır.

**Anahtar kelimeler:** Adrenal kanser; dediferansiye liposarkom; Cushing sendromu

### Introduction

Although adrenal tumors are a common condition, affecting up to 10% of the general population, most are benign adenomas, discovered incidentally on abdominal imaging (1). The malignant form, called adrenocortical carcinoma (ACC) is a rare condition with an incidence of 0.72 cases per million people according to the Surveillance, Epidemiology, and End Results (SEER) database (2). ACC seems to affect persons between the fourth and sixth decades of life (3,4).

The clinical presentation differs according to tumor size and the ability to overproduce steroids, which occurs in about 50% to 80% of the patients (3,5); one-third of the pa-

tients may present with local symptoms of mass growth, such as flank pain (3), and in 30% of the cases, the diagnosis occurs through an incidental finding of imaging diagnosis techniques (6).

After evaluation of the hormonal secretion profile, the confirmation of the diagnosis is made through histopathology based on the Weiss score (7).

Herein, we report a case that presented itself as an ACC but had unique histopathology of a liposarcoma, which is an extremely rare form of an adrenal tumor and was never described as a steroid secreting tumor. Informed consent was obtained from the patient.

**Address for Correspondence:** Lucas Ribeiro dos Santos, Clinic of Endocrinology and Metabology at Medical Sciences Faculty of Santos, São Paulo, Brazil

**Phone:** :+55 (13) 3202-4600 **E-mail:** lrs.endocrino@gmail.com

Peer review under responsibility of Turkish Journal of Endocrinology and Metabolism.

**Received:** 27 Aug 2019 **Received in revised form:** 06 Dec 2019 **Accepted:** 04 Jan 2020 **Available online:** 16 Jan 2020

1308-9846 / © Copyright 2020 by Society of Endocrinology and Metabolism of Turkey.

Publication and hosting by Türkiye Klinikleri.

This is an open access article under the CC BY-NC-SA license (<https://creativecommons.org/licenses/by-nc-sa/4.0/>)

## Case Report

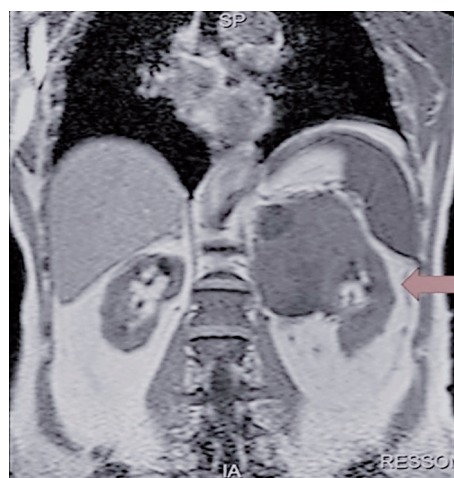
A 76-year-old male patient with a history of arterial hypertension and diabetes mellitus diagnosed about six months ago was referred to the endocrinology service center of Santa Casa de Misericórdia de São Paulo after a left adrenal mass was encountered on abdominal ultrasound, performed during the investigation of left flank pain. The patient had no typical features on physical examination.

Abdomen magnetic resonance imaging was performed with adrenal MRI protocol that showed a mass of 10.2×8.0×7.9 cm, irregular, with foci of necrosis, compromising pancreas, left adrenal and left kidney, and also a nodule on the lung base (Figure 1), which was better evaluated by CT scanning that showed sparse nodules bilaterally, with nonspecific characteristics.

Evaluation of hormonal production (Table 1) led us to the diagnosis of cortisol and androgens oversecretion.

The patient underwent left adrenalectomy plus distal pancreatectomy and left nephrectomy, and was later taken to standard post-operative care of Cushing's syndrome. After the surgery, the patient had normal blood pressure and glucose levels even after the withdrawal of antihypertensive and oral antidiabetic drugs.

The postoperative hormone profile showed lower levels of cortisol and androgens (Table 1), reinforcing our diagnosis of steroid overproduction. It was not possible to wean from prednisone at a dose of 5 mg per day due to postural hypotension.



**Figure 1:** MRI of the abdomen using adrenal MRI protocol, showing an extensive mass in the left adrenal, compromising the kidney and liver.

The anatomopathological analysis of the specimen showed fusocellular neoplasia, infiltrating the kidney, body, and tail of the pancreas and left adrenal gland, but an adrenal of normal characteristics; immunohistochemistry was positive for vimentin in diffuse pattern, cd34, s100 and cd68 protein in focal pattern, but negative for smooth muscle actin, myogenin, AE1/AE3, desmin, melan A, inhibin and chromogranin A, with Ki67 30%, resulting in analysis compatible with dedifferentiated liposarcoma. This anatomopathological analysis was re-evaluated by another pathologist, who maintained the diagnosis.

During follow-up visits, thorax tomography showed an increase in the number and volume of nodules, with metastatic character-

Table 1. Hormonal secretion profile.

Hormone	Pre operative	Post operative	Normal Range
Basal Cortisol	23.7 ug/dL	*3	3–18 ug/dL
Cortisol–Liddle 1 test	2.4 ug/dL	*3	< 1.8 ug/dL
ACTH1	8.6 pg/mL	-	5–65 pg/mL
DHEA-S2	994 ng/dL	243 ng/dL	120–870 ng/dL
17-OH-Progesterone	3.4 ng/mL	2.5 ng/mL	0.5–2 ng/mL
Androstenedione	6.10 ng/mL	0.60 ng/mL	0.6–3.1 ng/mL
Total Testosterone	599 ng/dL	329 ng/dL	250–1000 ng/dL
Plasma metanephrines	12 pg/mL	-	< 65 pg/mL
Plasma Normetanephrines	85 pg/mL	-	< 196 pg/mL
Aldosterone	*4	*4	

1. Adrenocorticotrophic hormone; 2. Dehydroepiandrosterone-sulfate; 3. Not performed due to inability to wean from prednisone; 4. Aldosterone levels were not measured for technical reasons.

istics. The patient was then referred to the oncology department where he is currently under radiotherapy.

## Discussion

We presented a clinical case of a patient with imaging and hormonal secretion pattern compatible with adrenocortical carcinoma, but with discordant anatomopathological analysis.

What seems to be the most interesting about this patient was his hormonal profile, indicating primary hypercortisolism and adrenal androgen excess; unfortunately, we were unable to evaluate the co-secretion of aldosterone due to logistic issues. The clinical evolution in the postoperative period, with hormonal re-evaluation demonstrating lower levels of testosterone and DHEA-S, correction of systemic arterial hypertension and the impossibility to wean from prednisone led us to believe that the sarcoma was indeed producing these steroids.

After performing a literature review in the Lilacs and Medline databases, we found no reports on steroid-secreting sarcomas. There are some reports of sarcomas with peptide hormone secretion, such as ACTH and chorionic gonadotropin (8-10).

There are some reports on myxoid ACCs, which are a rare subtype, presenting degeneration of the tumor or myxoid material produced by stromal fibroblasts (11); within this subtype of ACC, there are reports on lipomatous metaplasia. The lipomatous metaplasia of the ACC is still a matter of debate but could correspond to a reactive process in response to degeneration or a metaplastic process of the neoplastic cells (12).

Despite this different histological features, lipomatous metaplasia in myxoid ACCs still holds an identical immunohistochemical phenotype to conventional ACC-positive for inhibin, melan A, synaptophysin, and vimentin, with the variable reaction for cytokeratin (11), distinguishing it from our report, that was positive only for vimentin (which can occur in sarcomas) (13).

Primary liposarcomas of the adrenal gland are extremely rare, with only two reports in the literature, and it is extremely hard to differentiate it from retroperitoneal liposarcomas (14), which do not secrete steroids.

Radiological differentiation between liposarcomas and ACC can be challenging. On computed tomography, it usually presents negative Hounsfield unit (HU) values due to the high presence of fat (varying from -60 HU to +5 HU), contrasting with a usually high HU values obtained from ACC (above 20 HU); however, on MRI images, both can present high signal on T2-weighted sequences (15). Based on imaging techniques, the presumptive diagnosis of ACC will prevail, and differentiation will appear upon histopathological and immunohistochemistry analysis.

To the best of our knowledge, this is the first report on the clinical presentation of liposarcoma.

## Ethics

In compliance with ethics guidelines, informed consent was obtained from the patient included in the study.

## Source of Finance

During this study, no financial or spiritual support was received neither from any pharmaceutical company that has a direct connection with the research subject, nor from a company that provides or produces medical instruments and materials which may negatively affect the evaluation process of this study.

## Conflict of Interest

No conflicts of interest between the authors and / or family members of the scientific and medical committee members or members of the potential conflicts of interest, counseling, expertise, working conditions, share holding and similar situations in any firm.

## Authorship Contributions

Idea/Concept: José Viana Lima Júnior; Design: José Viana Lima Júnior; Control/Supervision: José Viana Lima Júnior; Data Collection and/or Processing: Lucas Ribeiro dos Santos; Analysis and/or Interpretation: Lucas Ribeiro dos Santos; Literature Review: Lucas Ribeiro dos Santos; Writing the Article: Márcio Luis Duarte; Critical Review: Márcio Luis Duarte; References and Fundings: José Viana Lima Júnior.

## References

1. Mansmann G, Lau J, Balk E, Rothberg M, Miyachi Y, Bornstein SR. The clinically inapparent adrenal mass: update in diagnosis and management. *Endocr Rev.* 2004;25:309-340. [[Crossref](#)] [[PubMed](#)]
2. Kerkhofs TM, Verhoeven RH, Van der Zwan JM, Dieleman J, Kerstens MN, Links TP, Van de Poll-Franse LV, Haak HR. Adrenocortical carcinoma: a population-based study on incidence and survival in the Netherlands since 1993. *Eur J Cancer.* 2013;49:2579-2586. [[Crossref](#)] [[PubMed](#)]
3. Fassnacht M, Allolio B. Clinical management of adrenocortical carcinoma. *Best Pract Res Clin Endocrinol Metab.* 2009;23:273-289. [[Crossref](#)] [[PubMed](#)]
4. Bilimoria KY, Shen WT, Elaraj D, Bentrem DJ, Winchester DJ, Kebebew E, Sturgeon C. Adrenocortical carcinoma in the United States: treatment utilization and prognostic factors. *Cancer.* 2008;113:3130-3136. [[Crossref](#)] [[PubMed](#)]
5. Allolio B, Fassnacht M. Clinical review: adrenocortical carcinoma: clinical update. *J Clin Endocrinol Metab.* 2006;91:2027-2037. [[Crossref](#)] [[PubMed](#)]
6. Fassnacht M, Allolio B. Epidemiology of adrenocortical carcinoma. In: Hammer G, Else T, eds. *Adrenocortical Carcinoma*. 1<sup>st</sup> ed. New York, NY: Springer; 2010. p.23-9. [[Crossref](#)]
7. Aubert S, Wacrenier A, Leroy X, Devos P, Carnaille B, Proye C, Wemeau JL, Lecomte-Houcke M, Lecomte E. Weiss system revisited: a clinicopathologic and immunohistochemical study of 49 adrenocortical tumors. *Am J Surg Pathol.* 2002;26:1612-1619. [[Crossref](#)] [[PubMed](#)]
8. Stevens EE, Aquino J, Barrow N, Lee YC. Ectopic production of human chorionic gonadotropin by synovial sarcoma of the hip. *Obstet Gynecol.* 2013;121:468-471. [[PubMed](#)]
9. Schöffski P, Sweldens C, Vanderbeeken MC, Forceville K, Vandenbroucke J, Dubin M, Debiec-Rychter M, Wozniak A, Sciort R. Retroperitoneal dedifferentiated liposarcomas with production of  $\beta$ -human chorionic gonadotropin--a distinct sarcoma entity? *Onkologie.* 2011;34:122-125. [[Crossref](#)] [[PubMed](#)]
10. More J, Young J, Reznik Y, Raverot G, Borson-Chazot F, Rohmer V, Baudin E, Coutant R, Tabarin A; Groupe Français des Tumeurs Endocrines (GTE). Ectopic ACTH syndrome in children and adolescents. *J Clin Endocrinol Metab.* 2011;96:1213-1222. [[Crossref](#)] [[PubMed](#)]
11. Weissferdt A, Phan A, Suster S, Moran CA. Myxoid adrenocortical carcinoma: a clinicopathologic and immunohistochemical study of 7 cases, including 1 case with lipomatous metaplasia. *Am J Clin Pathol.* 2013;139:780-786. [[Crossref](#)] [[PubMed](#)]
12. Izumi M, Serizawa H, Iwaya K, Takeda K, Sasano H, Mukai K. A case of myxoid adrenocortical carcinoma with extensive lipomatous metaplasia. *Arch Pathol Lab Med.* 2003;127:227-230. [[PubMed](#)]
13. Hamlat A, Saikali S, Gueye EM, Le Strat A, Carsin-Nicol B, Brassier G. Primary liposarcoma of the thoracic spine: case report. *Eur Spine J.* 2005;14:613-618. [[Crossref](#)] [[PubMed](#)] [[PMC](#)]
14. Lam AK. Lipomatous tumours in adrenal gland: WHO updates and clinical implications. *Endocr Relat Cancer.* 2017;24:R65-R79. [[Crossref](#)] [[PubMed](#)]
15. Zhao J, Sun F, Jing X, Zhou W, Huang X, Wang H, Zhu Y, Yuan F, Shen Z. The diagnosis and treatment of primary adrenal lipomatous tumours in Chinese patients: a 31-year follow-up study. *Can Urol Assoc J.* 2014;8:E132-136. [[Crossref](#)] [[PubMed](#)] [[PMC](#)]