

Presence of Multiple Endocrine Neoplasia-1 Mutations in Patients with Primary Hyperparathyroidism Detected on Clinical and Sonographical Suspicion: Report of 2 Novel Mutations

ORIGINAL ARTICLE
Endocrinol Res Pract. 2023;27(2):71-77

ABSTRACT

Objective: This study aims to evaluate the presence of multiple endocrine neoplasia-1 mutations in patients with primary hyperparathyroidism detected on clinical and sonographical suspicion.

Methods: We scanned the medical records of 361 patients with primary hyperparathyroidism between January 2010 and December 2017.

Results: Fourteen of 361 patients (i.e., 2 males and 12 females) with primary hyperparathyroidism were evaluated genetically upon clinical and sonographical suspicion. Menin gene mutations were found in 3 of 14 patients (21.4%) patients. The frequency of multiple endocrine neoplasia-1 (n=3) was estimated to be 0.83% in all patients with primary hyperparathyroidism (n=361). Data of 4 patients with menin mutation analyses were as follows: case 1: A 37-year-old man presented with a 14-year history of recurring nephrolithiasis. He was diagnosed with primary hyperparathyroidism. Genetic analysis was reported as multiple endocrine neoplasia-1: c.643_646delACAG (p.Thr215Serfs*13) heterozygote; case 2: A 35-year-old man with primary hyperparathyroidism and prolactinoma was diagnosed. Genetic analysis was reported as multiple endocrine neoplasia-1: c.654+1G>A heterozygote; case 3: A 26-year-old woman with hyperammonemia, partial empty sella, and hyperprolactinemia was evaluated. Genetic testing revealed heterozygote genomic changes in c984c>a in the multiple endocrine neoplasia-1 gene on the seventh exon; case 4: A 27-year-old man was diagnosed with nephrolithiasis when he was 19 years old. He had both primary hyperparathyroidism and prolactinoma. Multiple endocrine neoplasia-1 and CDKN1B genetic mutation analyses were negative. Because mutation-negative syndromes could not be ruled out, a neck exploration was performed, and a parathyroid adenoma was excised.

Conclusions: Patients with primary hyperparathyroidism should be evaluated for multiple endocrine neoplasia-1 mutations upon clinical and sonographical suspicion. It should be noted that an individual with the multiple endocrine neoplasia-1 gene mutation has a 100% penetrance up to the age of 40-50 years. Additionally, 2 novel multiple endocrine neoplasia-1 mutations were identified.

Keywords: Genetic analysis, menin, multiple endocrine neoplasia, mutation, primary hyperparathyroidism

Introduction

Inherited syndromes are found in a few patients with primary hyperparathyroidism (PHPT; <5%), and they primarily cause multiglandular disease.¹ Multiple endocrine neoplasia (MEN)-1, MEN-2a, MEN-4, and severe neonatal PHPT (hyperparathyroidism—jaw tumor syndrome) are the syndromes associated with PHPT.² The most common MEN-1 component is PHPT with multiple parathyroid tumors. Furthermore, it is frequently the first symptom in most patients. Patients with MEN-1 develop hyperparathyroidism in 2 to 4 decades, approximately 20 years earlier than sporadic cases.³ The PHPT is expected to manifest in these patients until they are 50 years old.^{3,4} The prevalence of MEN-1 is approximately 2 per 100 000,⁵ and the incidence in patients with parathyroid adenoma ranges from 1% to 18%.³ The PHPT, pituitary adenoma, and gastroenteropancreatic neuroendocrine tumor are common in patients with MEN-1.^{6,7} Multiple endocrine neoplasia-1 is diagnosed in patients with 2 or more primary MEN-1 tumors or patients with one of the MEN-1 tumors and a family history of MEN-1.² Multiple endocrine neoplasia-1 is an autosomal dominant disease caused by a single mutant gene (OMIM gene 613733). The MEN-1 gene is a tumor suppressor located

Muhammet Cüneyt Bilginer¹ 

Cevdet Aydın² 

Sevgül Faki³ 

Oya Topaloğlu⁴ 

Hanife Saat⁴ 

Buşranur Çavdarlı⁵ 

Reyhan Ersoy² 

Bekir Çakır² 

¹Department of Endocrinology and Metabolism, Karadeniz Technical University Faculty of Medicine, Trabzon, Turkey

²Department of Endocrinology and Metabolism, Ankara Yıldırım Beyazıt University Faculty of Medicine, Ankara, Turkey

³Department of Endocrinology and Metabolism, Ankara City Hospital, University of Health Sciences, Ankara, Turkey

⁴Department of Medical Genetics, Ankara Diskapi Yıldırım Beyazıt Education and Research Hospital, Ankara, Turkey

⁵Department of Medical Genetics, Ankara City Hospital, University of Health Sciences, Ankara, Turkey

Corresponding author:
Muhammet Cüneyt Bilginer
✉ cuneytbilginer@hotmail.com

Received: April 1, 2022

Revision Requested: August 15, 2022

Last Revision Received: December 19, 2022

Accepted: December 22, 2022

Publication Date: April 20, 2023

Cite this article as: Cüneyt Bilginer M, Aydın C, Faki S, et al. Presence of multiple endocrine neoplasia-1 mutations in patients with primary hyperparathyroidism detected on clinical and sonographical suspicion: report of 2 novel mutations. *Endocrinol Res Pract.* 2023;27(2):71-77.

DOI: 10.5152/erp.2023.220405



Copyright © Author(s) – Available online at <http://endocrinolrespract.org>
This journal is licensed under a Creative Commons (CC BY-NC-SA) 4.0 International License.

on the long arm of chromosome 11 (11q13).⁸ This gene synthesizes the protein menin, which has 610 amino acids.⁹ Menin somatic gene mutations are found in 12%-17% of patients with sporadic parathyroid adenomas.¹⁰ More than 90% of patients with MEN-1 have lost heterozygosity, which supports Knudson's 2-hit hypothesis.¹¹ The MEN-1 gene consists of 10 exons and is encoded by 1830-bp.¹¹ Menin has been found to interact with activating protein-1, Jun-D, and Jun-C in the transcription arrangement, causing suppression of Jun-mediated transcriptional activation.¹² Menin also inhibits transcription mediated by the nuclear factor kappa beta.¹² A genetic test is recommended in the following situations: a family history of PHPT, young patients, multiglandular parathyroid disease, tumors associated with MEN-1, MEN-2, or HPT-JT, and patients with symptoms related to these syndromes.¹³ The PHPT is rarely the first symptom of patients with MEN-2; therefore, serum calcitonin measurement will be useful in young patients with PHPT and concomitant thyroid nodules, even if they have no apparent MEN-2 symptoms.¹⁴ In this study, we presented the results of genetic analyses of patients with PHPT. This topic is important, in our opinion, because there are no data for our country in the literature. However, the present study has a cross-sectional design, and we believe that its results are generalizable because our hospital is a referral center and many patients are referred to our clinic from other facilities.

Materials and Methods

This retrospective study was approved by the Ethics Committee of Ankara Yıldırım Beyazıt University, Faculty of Medicine (Date: July 22, 2020, Decision No: 26379996/64). The study protocol followed the tenets of the 1964 Declaration of Helsinki. Written informed consent was obtained from all participants who participated in this study.

Study Population

A total of 361 patients diagnosed with PHPT between January 2010 and December 2017 had their medical records reviewed retrospectively. The inclusion criteria of the study were as follows: patients over the age of 18 with a confirmed biochemical diagnosis of PHPT (hypercalcemia and inadequately higher serum parathyroid hormone (PTH) level). Patients on lithium treatment and with a history of neck radiation were excluded. Each patient underwent the same biochemical and imaging procedures and then genetic testing. Based on clinical suspicion, we presented the data of 14 patients with genetic mutation analyses, such as patients with PHPT below 30 years old, multiglandular parathyroid adenomas below 40 years old, or recurrent parathyroid adenomas, having a family history of PHPT, and having tumors associated with MEN-1 (pancreatic islet and anterior pituitary tumors), MEN-2, or HPT-JT, and symptoms associated with these syndromes.³

Genetic Analysis

Genetic analysis was performed in the Medical Genetic Laboratories of Ankara Diskapi Yıldırım Beyazıt and Ankara Numune Education and Research Hospitals. Genomic DNA was extracted from peripheral

lymphocytes using the QIAcube automated DNA isolation system (QIAGEN, Hilden, Germany) according to the manufacturer's instructions. Exons 2-10 of the MEN-1 gene (transcript: NM_000244.3) were sequenced using GML® Seqfinder Sequencing System MEN-1 Kit via ABI 3130 automated DNA sequencer system (Applied Biosystems, Waltham, Massachusetts, USA). We used the SeqScape v2.6 program to analyze the results. The variant's pathogenicity was assessed in accordance with the recommendations of the American College of Medical Genetics (ACMG) and Genomics and the Association for Molecular Pathology.¹⁵

Laboratory Examinations

Biochemical data from the patient's records included serum calcium (Ca; mg/dL), phosphorus (mg/dL), albumin (g/dL), alkaline phosphatase (ALP; IU/L), creatinine (mg/dL), PTH (pg/mL), 25-hydroxy vitamin D (µg/L), and 24-hour urinary Ca (mg/day) excretion, insulin (mIU/mL), gastrin (pg/mL), and prolactin (µg/L). Reference ranges for vitamin D, plasma intact PTH, total Ca, phosphorus, albumin, ALP, Cr, 24-hour urinary Ca excretion, insulin, and gastrin were 20-80 µg/L, 15-60 pg/mL, 8.5-10.5 mg/dL (Roche Diagnostics, Basel, Switzerland), 2.5-4.5 mg/dL, 3.5-5.2 g/dL, 36-113 IU/L, 0.5-1.1 mg/dL, 25-300 mg/day, <29.1 mIU/mL, and <110 pg/mL, respectively. Additionally, renal ultrasound (US) and dual-energy x-ray absorptiometry (DEXA) were performed to evaluate nephrolithiasis and bone mineral density, respectively. The B-mode US was used to localize parathyroid lesions. Parathyroid scanning was performed using intravenously injected 15-mCi Technetium-99 m-methoxy-isobutyl-isonitrile (MIBI).

Statistical Analysis

All statistical analyses were performed using the Statistical Package for the Social Sciences 23.0 software package (SPSS, Inc., Chicago, Ill, USA). Descriptive statistics for the continuous variables were expressed as mean ± SD and categorical variables as numerics and percent (%).

Results

The present study was based on retrospective screening of 361 patient data from approximately 7 years. Multiple endocrine neoplasia-1 was found in 0.83% (n=3) of or center's PHPT patients (n=361). The mean age of the patient group was 53.75 ± 12.89 (20-82) years. The genetic analysis was performed on 14 patients with PHPT (2 men and 12 women; mean aged 31.2 ± 5.7 years; 24-43 years). The number of patients aged below 30 years, between 30 and 40 years, and over 40 years was 7 (50%), 6 (42.9%), and 1 (7.1%), respectively. Genetic analysis was required in 14 patients. Menin gene mutations were found in 3 (21.4%) patients (Table 1). The remaining 11 patients were found to be menin gene mutation free. One patient had MEN-1-related clinical features but a negative menin gene mutation (case 4). The data of 3 patients with menin gene mutation were as follows:

Case 1: A 37-year-old male patient had hypercalcemia in biochemical analysis 4 years ago (serum Ca: 11.0 mg/dL, serum albumin: 4.79 g/dL, and serum creatinine: 0.76 mg/dL). He had nephrolithiasis

Table 1. Findings of Patients with Positive Menin Gene Mutation				
	Age	Exon	Codon	Mutation
Case 1	37	Third exon	215th amino acid	MEN-1: c.643_646delACAG (p.Thr215Serfs*13)/heterozygote
Case 2	35	Third exon	218th amino acid	MEN-1: c.654+1G>A/heterozygote
Case 3	26	Seventh exon	328th amino acid	MEN 1: at seventh exon c984c>a/heterozygote

Table 2. Laboratory Data of the Patient				
	Case 1	Case 2	Case 3	Case 4
Serum calcium (mg/dL)	11.41	11.6	11.2	11.9
Serum albumin (g/dL)	4.88	5.00	4.68	4.9
Corrected serum calcium (mg/dL)	10.7	10.6	10.8	11.1
Serum phosphorus (mg/dL)	2.20	2.84	2.30	2.50
Serum creatinine (mg/dL)	0.7	0.8	0.58	0.90
PTH (pg/mL)	250	97	142	135
ALP (IU/L)	131		105	162
24-hour urinary calcium excretion (mg/day)	448	487	327	466
Fractionated urinary calcium excretion	0.02	0.02	0.02	0.02
25-Hydroxy vitamin D (µg/L)	35.0	28.6	18.0	44
Serum prolactin ^a (µg/L)	15	235	67	246
Serum insulin (mIU/mL)	17.5	10.1	22.1	17
Serum gastrin (pg/mL)	20.4	18.8	29.0	0.1

ALP, alkaline phosphatase; PTH, parathyroid hormone.
^aThe remaining anterior pituitary hormones were in normal range.

for 14 years. The laboratory values in his first presentation to our hospital were as follows: serum Ca, 11.41 mg/dL; serum albumin, 4.88 g/dL; corrected serum Ca, 10.7 mg/dL; serum creatinine, 0.7 mg/dL; serum phosphorus, 2.2 mg/dL; PTH, 250 pg/mL; ALP, 131 IU/L; 24-hour urinary Ca excretion, 448 mg/day; and fractionated urinary Ca excretion, 0.02 (Table 2). During a neck US examination, a 4.4 × 6.1 × 6.6-mm diameter well-defined iso-hypoechoic nodular lesion was detected adjacent to the left lobe posterior region. The genetic laboratory examinations scintigraphy revealed a radionuclide uptake in the thyroid's left inferior lobe region, which was diagnosed as a parathyroid adenoma. Femoral neck, lumbar vertebral, and forearm 1/3 distal T/Z scores were -0.1/0.3, -1.3/-1.2, and -1.3/1.2, respectively. The anterior hypophyseal hormones were within normal limits.

MEN1(NM: 000244.3)

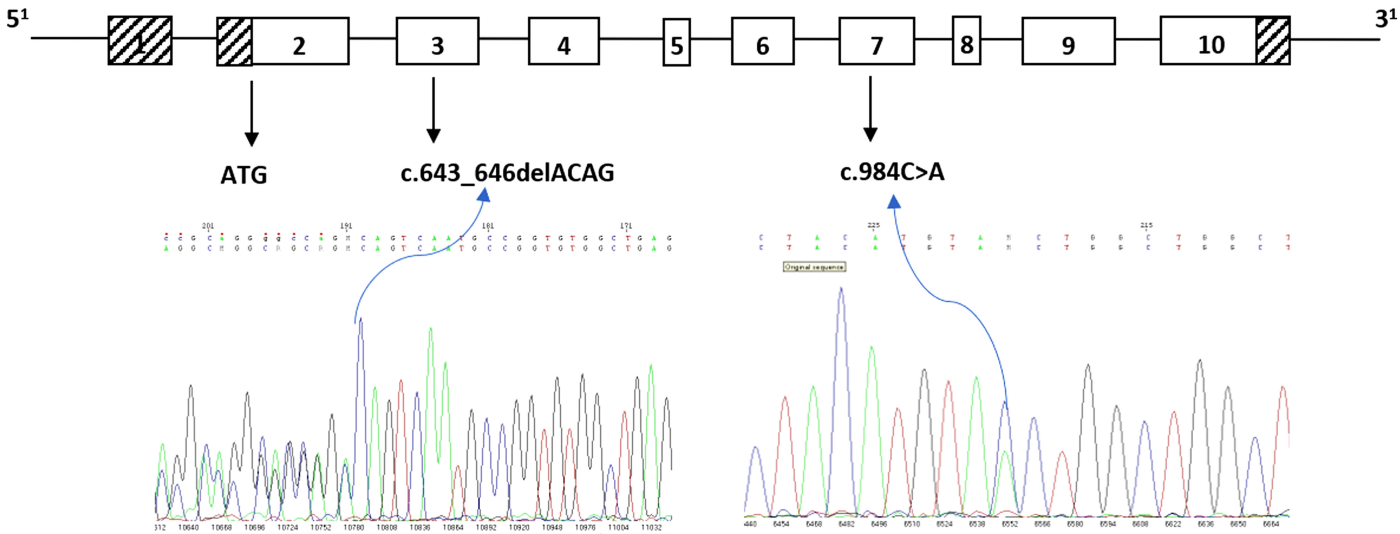


Figure 1. Schematic presentation of the MEN-1 gene structure and Sanger sequence of novel mutations. Exonic positions of the mutations and variants on the electropherograms are indicated by arrows. ATG is the start codon. MEN-1, multiple endocrine neoplasia-1.

Pancreatic hormone levels were also insignificant (serum insulin: 17.5 mIU/mL and serum gastrin: 20.4 pg/mL). Because the patient had PHPT and clinical findings beginning in his third decade and his US findings were most indicative of parathyroid hyperplasia, a genetic analysis was performed. The DNA sequence analysis was used to examine MEN-1 gene-associated whole exons and exon-intron junctions. A heterozygous genomic change in the third exon c.643_646delACAG (p.Thr215Serfs*13) resulted in deficient protein synthesis due to frame sliding and early stop codon (Figure 1). According to genetic analysis section-2015 criteria, this genomic change was determined to be pathogenic.¹⁵ The result was compatible with MEN-1. Other tumoral components were insignificant in the clinical and laboratory evaluations of the patient with MEN-1. A subtotal parathyroidectomy was performed. Right superior parathyroid hyperplasia, right inferior and left superior half parathyroidectomy, left inferior parathyroidectomy, and thymectomy were reported histopathologically. During the follow-up period, serum Ca and PTH levels were 9.5 mg/dL and 77 pg/mL, 10.2 mg/dL and 81 pg/mL, and 10.0 mg/dL and 140 pg/mL in 1, 2, and 3 years, respectively, after the operation. At the end of the third year of follow-up, anterior hypophyseal hormones, serum insulin, and gastrin levels were within normal limits.

Case 2: A 35-year-old male patient with hypercalcemia was admitted to our outpatient clinic. Laboratory values were as follows: serum Ca, 11.6 mg/dL; albumin, 5 g/dL; corrected serum Ca, 10.6 mg/dL; serum PTH, 97 pg/mL; serum phosphorus, 2.84 mg/dL; 24-hour urinary Ca excretion, 487 mg/day; and fractionated urinary Ca excretion, 0.02. The serum prolactin level was 235 µg/L, and macroprolactinemia was detected as positive (Table 2). There were millimetric sonographically low-risk nodules in the thyroid gland in the neck US examination, but parathyroid adenoma was found in parathyroid regions. There was no typical scintigraphic finding associated with adenoma in parathyroid scintigraphy (dual-phase MIBI). Bone mineral density values were low for age (femur neck T/Z scores: -0.4/0.2 and lumbar spine

total T/Z scores: $-2.3/-2.3$). The urinary US examination revealed no evidence of urolithiasis. There was a 3×7 -mm hypointense nodular signaling consistent with hypophyseal adenoma in magnetic resonance imaging (MRI). Other MEN-1-associated tumoral components (insulin: 10.1 mIU/mL and gastrin: 18.8 μ g/L) were clinically and laboratory insignificant. The patient was diagnosed with PHPT and prolactinoma. He underwent genetic testing because he was below 50 years old and had 2 primary MEN-1-associated tumors.³ The genetic analysis revealed a heterozygous MEN-1: c.654+1G>A mutation at the 218th codon of exon 3. This mutation has been found in patients with MEN-1 syndrome in online databases (Human Gene Mutation Database, Mutation Taster) and the literature. A subtotal parathyroidectomy was recommended after the patient was diagnosed with MEN-1 syndrome. The patient's medical records after surgery were not obtained.

Case 3: A 26-year-old female patient was admitted to our center with a history of hyperammonemia. She had a transsphenoidal hypophyseal surgery for prolactinoma when she was 15 years old, but there was no histopathology report. She received replacement therapy for a while before it was discontinued based on the results of normal dynamic tests. The hypophyseal MRI appeared like a rim on the right half of the hypophysis and was 2.5 mm tall on the left half of the gland. The infundibulum is revealed as it is replaced to the left. The patient's previous laboratory values showed slightly elevated serum Ca levels (10.0-10.6 mg/dL) 7 years ago. Her laboratory values at the time of admission to our center were as follows: serum Ca, 11.2 mg/dL; serum albumin, 4.68 g/dL; corrected Ca, 10.8 mg/dL; serum PTH, 142 pg/mL; serum phosphorus, 2.3 mg/dL; serum creatinine, 0.58 mg/dL; ALP, 105 IU/L; 24-hour urinary Ca excretion, 327 mg/day; and fractionated urinary Ca excretion, 0.02 (Table 2). Neck US revealed a $7.4 \times 6.1 \times 7.3$ -mm regularly bordered hypoechoic nodular lesion in the thyroid gland's right inferior posterior region and a $7.4 \times 5.6 \times 7.0$ -mm iso-hypoechoic nodular lesion in the gland's left inferior region. Both lesions were suspected of being parathyroid adenomas. However, no parathyroid scintigraphy (MIBI) had no pathological pharmaceutical enhancement in the early phase (10th minute), the thyroid gland was partially washed out, and less activity persisted in the inferior half of the right and left lobes in the late phase. The PTH washout levels in the left inferior and right inferior lesions were 5789 and 18.06 pg/mL, respectively. At bone mineral densitometry (DEXA), the femur neck, lumbar vertebra 1-4, and forearm 1/3 T/Z scores were 0.1/0.1, 0.1/0.2, and $-0.6/-0.5$, respectively. Despite a serum prolactin value of 67 μ g/L, other hormonal values were insignificant. Serum insulin was 22.1 mIU/mL, and gastrin was 29 pg/mL in a pancreatic gland hormonal evaluation, both within normal ranges. An abdominal MRI revealed no mass at the pancreatic gland, and the adrenal glands were found to be normal. Because the patient had 2 primary MEN-1-associated tumors before the age of 50 years, a genetic analysis was performed.³ The genetic mutation analysis revealed a heterozygous c984C>A genomic change at the seventh exon of the MEN-1 gene (e7c-het; Figure 1), which was classified as pathogenic by ACMG-2015 criteria.¹⁵ Histopathology revealed benign thymic tissue and hyperplastic parathyroid glands after surgery (thymectomy, gland parathyroidectomy, or forearm implantation). The patient was closely monitored and had normocalcemia 3 years after surgery. Serum Ca and PTH levels at the end of 1-3 years were 8.9 mg/dL and 34.0 pg/mL, 9.1 mg/dL and 34.5 pg/mL, and 9.2 mg/dL and 55.3 pg/mL, respectively.

Case 4: A 27-year-old male patient was admitted with a history of nephrolithiasis since he was 19 years old. This patient was distinct from others with a negative MEN-1 mutation because he had concomitant PHPT and prolactinoma. The patient was evaluated for the etiology of nephrolithiasis when he was 18 years old, and his serum Ca, serum albumin, and corrected Ca were 9.8 mg/dL, 4.8 g/dL, and 9.2, respectively. He was evaluated at our center 8 years after his first complaint, and his laboratory values were as follows: serum Ca, 11.9 mg/dL; serum albumin, 4.9 g/dL; serum phosphorus, 2.5 mg/dL; serum creatinine, 0.9 mg/dL; serum PTH, 135 pg/mL; ALP, 162 IU/L; 24-hour urinary Ca excretion, 466 mg/day; fractionated urinary Ca excretion, 0.02; prolactin, 246 μ g/L; gastrin, <0.1 μ g/L; and insulin, 17 mIU/mL (Table 2). The femur neck, lumbar vertebra, and forearm 1/3 Z scores in bone mineral densitometry were -1 , -1.8 , and -2.4 , respectively. An MRI of the hypophysis revealed a 7×5 -mm adenoma in the anterior hypophysis' right half. The abdominal MRI revealed no pathology in the pancreatic gland. Neck US, neck computed tomography (CT), thorax CT, and parathyroid MIBI scintigraphy were insignificant for parathyroid adenoma. Because the patient had no family history of hypercalcemia, the initial MEN-1 mutation analysis was performed. The MEN-1 mutation was found negative. Subsequently, CDKN1B gene mutation analysis was performed on MEN-4. The MEN-4 analysis also reported a negative. However, mutation-negative MEN-1 to MEN-4 syndromes were not ruled out; therefore, neck exploration was planned, and if an adenoma was not found during the operation, a subtotal parathyroidectomy (3.5 gland excision) was planned. During the neck exploration, a parathyroid adenoma was found and excised. Histopathology reported an adenoma with 0-1 mitotic index and <1% Ki-67 index at 10 large magnification areas. After surgery, serum Ca and PTH levels were normal (serum Ca: 9.65 mg/dL, serum albumin: 4.7 g/dL, serum PTH: 69 pg/mL, and 25-hydroxy vitamin D3: 12.3 μ g/L).

There were no atypical MEN-1-associated tumors in the patient, such as adrenocortical tumor, bronchial carcinoid, lipoma, angiofibroma, and collagenoma.

Discussion

Primary hyperparathyroidism is the most common (95%) finding in patients with MEN-1 and has no clinical sign in most patients.³ Hyperparathyroidism caused by MEN-1 usually appears in the second to fourth decades of life.¹⁶ The present study screened the medical records of 361 patients from a 7-year PHPT database, and 14 patients performed mutation analyses. The mean age of patients with mutation analysis was 24-43 years. Seven (50%) patients were under the age of 30 years, 6 (42.9%) patients were between the ages of 30 and 40 years, and 1 (7.1%) patient was over 40 years old. Two MEN-1 mutation patients were between 30 and 40 years, and 1 patient was under 30 years old. Penetration of 100% for genetic transition is a continuous process until the age of 40-50 years.⁴ In the present study, the frequency of MEN-1 ($n=3$) was 0.83% in patients with PHPT ($n=361$). The incidence of MEN-1 is estimated to be 1%-18% in patients with PHPT.³ The incidence of MEN-1 in our patients with PHPT appears to be lower than the assumed frequency. The incidence of MEN-1 in patients with PHPT is estimated to be closer to the lower end of this range based on data from studies.³⁻⁷ In this respect, we believe our findings are consistent with the literature.

We presented retrospective clinical and laboratory data from patients with PHPT referred to our hospital from many different centers in our city. Although it appears to be single-center cross-sectional

data, we believe the results also reflect regional data due to the localization of our city and hospital as a reference center. A few studies have collected data on the frequency of MEN-1 in patients with PHPT. With multicenter epidemiological studies conducted across the country, we believe that the incidence of MEN-1 will be clarified and added to the literature.

The role of DNA analysis in patients with MEN-1 is not significant when compared with MEN-2a.^{3,17} It is primarily due to a lack of data related to MEN-1-associated tumor detection before clinical presentation, which affects morbidity and mortality.^{3,17} According to the cases, the related situations for genetic analysis should be evaluated.^{17,18} Indications for MEN-1 genetic testing include 2 or more MEN-1-associated tumors, multiple parathyroid tumors in patients over 40 years, recurrent hyperparathyroidism, gastrinoma, or multiple pancreas neuroendocrine tumors.² Another advantage of genetic analysis is that it can detect cases that do not have mutations and do not require regular follow-up. The presence of a mutation in an asymptomatic member of a family emphasizes the importance of close monitoring.³ Untreated patients with MEN-1 have a lower survival rate. The risk of death is 50% until the age of 50 years. Furthermore, the malignant tumoral course or sequela of the disease causes mortality in 50%-70% of patients with MEN-1.^{3,19,20}

It is important to determine whether an individual has the MEN-1 mutation because MEN-1 mutation-positive patients have more aggressive disease and early tumoral recurrence than mutation-negative patients.³ In the 10 years since the discovery of the MEN-1 gene, 1336 gene mutations (85% germline and 15% somatic) have been reported.¹² Finally, 1698 total mutations and 377 different mutation types have been detected according to the data from the universal mutation database MEN-1 (UMD-MEN-1).^{21,22} Case 1 mutation analysis revealed a heterozygous genomic change in c.643_646delACAG (p.Thr215Serfs*13) at the third exon. The mutation at this region (215th aa) has yet to be identified compared with the data in the UMD-MEN-1 database.^{21,22} However, the aforementioned genomic change has been classified as pathogenic by the ACMG-2015 criteria.¹⁵ Case 2 was found to be heterozygous for MEN-1: c.654+1G>A at the 218th codon of the third exon. In the database, 14 patients have mutations at the 218th codon. Furthermore, mutations at 654th and 652nd amino acids were found in 12 and 2 patients, respectively.^{21,22} Case 3 had a genomic change of c984C>A in the seventh exon of the MEN-1 gene (e7c-het), but this mutation at the 328th aa was not found in the database.^{21,22} Meanwhile, according to ACMG-2015 criteria, this mutation is pathogenic.¹⁵ The most common mutation-carrying positions are exon 10 (31.5%) and exon 2 (25.8%) based on UMD-MEN-1 database.^{21,22} However, Bassett et al²³ reported the most frequent mutations in exons 2, 3, and 10, and Kouvaraki et al²⁴ identified MEN-1 mutations in exons 2, 9, and 10. Our cases have mutations in exons 3 (10.6%) and 7 (6.3%), which are rarely seen. Mutation characteristics of MEN-1 gene are approximately 23% non-sense, 41% frame-shift, 6% deletion/insertion, 9% splice site, and 20% missense mutations.¹² Consequently, according to the UMD-MEN-1 database, 2 of our 3 patients had mutations at new aa positions.

The CDKN1B (CDK inhibitor genes) mutation is associated with MEN-4 and can cause 1%-2% of MEN-1-like findings in patients without MEN-1 mutation.²⁵ Furthermore, 5%-25% of patients do not have a MEN-1 gene mutation. It is suggested that these patients should be tested for mutations in the Ca-sensing receptor,

aryl hydrocarbon receptor protein (AIP), and Cell Division Cycle 73 (CDC73).²⁶ Additionally, the concurrent development of endocrine tumors associated with MEN-1 mutations is known to cause phenocopy.³ Case 4 had clinically MEN-1 components, but genetic analysis revealed no mutations associated with MEN-1 and MEN-4. Based on a study evaluating inconsistency between mutational and clinical data, it is suggested that phenocopy in a patient with familial MEN-1 can mimic MEN-1, causing a sporadic endocrine tumor, or it is thought to have concurrent two MEN-1 components associated with different etiologies.²⁷ In case 4, mutation-negative MEN-1 was not excluded preoperatively, so a subtotal parathyroidectomy was planned if no adenoma was found during neck exploration. A solitary parathyroid adenoma was found and excised in this patient; no subtotal parathyroidectomy was required. During the follow-up period, there has been no relapse. As a result of the causes mentioned earlier, this patient did not consider syndromic reasons.

Patients with classic MEN-1 syndrome are at risk for recurrent hyperparathyroidism even after a successful subtotal parathyroidectomy. According to the literature, 20%-60% of patients had permanent or recurrent hypercalcemia after 10 years.^{3,28} One patient in our case series had subtotal parathyroidectomy, while the other had total parathyroidectomy and autotransplantation. In both cases, no recurrence has been observed after a 3-year follow-up. According to the current literature, we also believe that total or subtotal parathyroidectomy should be performed rather than minimally invasive surgery and that patients should have a periodic follow-up after surgery.² Although thymectomy, in addition to subtotal parathyroidectomy, is a contentious issue, thymectomy has been performed due to the possibility of intrathymic parathyroid tissue or being a future pathological PTH source. Furthermore, prophylactic thymectomy can prevent the development of carcinoid tumors in these patients who are at risk for thymic carcinoids.²⁹

Approximately 40% of patients have anterior hypophyseal tumors (prolactinoma, somatotropinoma, corticotropinoma, and nonfunctional hypophyseal adenoma). Prolactinoma is expected to occur in 20% of patients with MEN-1.^{3,5,30} In the present study, 2 of 3 patients with mutation-positive MEN-1 had a history of prolactinoma (case 2 or 3). Prolactinoma is detected as an initial finding in 15% of cases.³ Case 3 had hypophyseal surgery when she was 15 years old. It has been reported that hypophyseal adenomas are initiated at 38.0 ± 15.3 years (12-83 years).³¹ The same study showed an increased frequency of hypophyseal macroadenoma in patients associated with MEN-1.³¹

Pancreatic neuroendocrine tumors (NETs) (pancreatic islet tumors, gastrinomas, insulinomas, glucagonomas, and vasoactive intestinal polypeptidomas) have been observed in 40%-70% of patients with MEN-1.³ Biochemical and radiologic (MRI) follow-up was performed periodically up to 40 years of age for cases 1 and 2 and 30 years of age for case 3. No penetration of the pancreatic tumor was found. Endoscopic US results showed that the prevalence of nonfunctional pancreatic tumors varies between 30% and 80%.³²⁻³⁵ However, there has been no consensus on radiological scanning. Assessment (MRI, CT, or endoscopic US) is recommended due to the patient's situation. It has been suggested that a scan for possible adrenal tumors be performed during the same visit.³

However, when the bone mineral densitometry was evaluated, cases 1 and 3 had normal bone mineral density, whereas case 2 had low

bone density when compared with values of individuals of the same ages. Patients with MEN-1 syndrome have lower bone mineral density than those with sporadic PHPT.¹⁶ More research with a larger sample size of patients with MEN-1 is needed to clarify this issue. The periodic evaluation of symptoms and clinical findings is important in the follow-up of patients with MEN-1 diagnosed with PHPT. Follow-up visits should include an evaluation of functional status and possible findings associated with compression (galactorrhea, amenorrhea, headache, and vision problems) for hypophyseal tumor and pancreatic tumor (symptoms and findings of hypoglycemia, peptic ulcer disease, and diarrhea). Furthermore, anterior hypophyseal functions (PRL and IGF-1) and markers associated with pancreatic neuroendocrine tumor (gastrin, fasting glucose, insulin, chromogranin, pancreatic polypeptide, glucagon, and VIP) should be evaluated in the follow-up.³

We suggested genetic analysis for other family members according to the MEN-1 gene testing results of peripheral blood samples of the index cases.³ It is known that 10% of relatives of patients with familial isolated hyperparathyroidism have detectable MEN-1 mutation.³⁶ When a pathologic mutation is detected in the index case, mutation situations specific to the family can be identified for at-risk relatives.³ Suppose no DNA tests for scanning of asymptomatic family members are used. In that case, serum PTH and vitamin D measurement, in addition to serum Ca, improve scanning sensitivity and specificity.³⁰

Conclusion

Patients with primary hyperparathyroidism should be evaluated for MEN-1 mutations upon clinical and sonographical suspicion. It should be noted that an individual with the MEN-1 gene mutation has a 100% penetrance up to the age of 40-50 years.

Ethics Committee Approval: This retrospective study was approved by the Ethics Committee of Ankara Yıldırım Beyazıt University, Faculty of Medicine. The study protocol followed the tenets of the 1964 Declaration of Helsinki (Date: July 22, 2020, Decision No: 26379996/64).

Informed Consent: Written informed consent was obtained from all participants who participated in this study.

Peer-review: Externally peer-reviewed.

Author Contributions: Concept – M.C.B., C.A.; Design – R.E., B.C.; Supervision – C.A., O.T.; Funding – Materials – M.C.B., S.F., B.Ç., H.S.; Data Collection and/or Processing – C.A., O.T.; Analysis and/or Interpretation – M.C.B., S.F.; Literature Review – M.C.B., S.F.; Writing – M.C.B., S.F.; Critical Review – C.A., O.T., R.E., B.C.

Declaration of Interests: The authors have no conflicts of interest to declare.

Funding: The authors declared that this study has received no financial support.

References

- Miedlich S, Krohn K, Paschke R. Update on genetic and clinical aspects of primary hyperparathyroidism. *Clin Endocrinol (Oxf)*. 2003;59(5):539-554. [\[CrossRef\]](#)
- Brewer K, Costa-Guda J, Arnold A. Molecular genetic insights into sporadic primary hyperparathyroidism. *Endocr Relat Cancer*. 2019;26(2):R53-R72. [\[CrossRef\]](#)
- Thakker RV, Newey PJ, Walls GV, et al. Clinical practice guidelines for multiple endocrine neoplasia type 1 (MEN-1). *J Clin Endocrinol Metab*. 2012;97(9):2990-3011. [\[CrossRef\]](#)
- Trump D, Farren B, Wooding C, et al. Clinical studies of multiple endocrine neoplasia type 1 (MEN-1). *Qjm*. 1996;89(9):653-669. [\[CrossRef\]](#)
- Brandi ML, Gagel RF, Angeli A, et al. Guidelines for diagnosis and therapy of MEN type 1 and type 2. *J Clin Endocrinol Metab*. 2001;86(12):5658-5671. [\[CrossRef\]](#)
- Thakker RV. Multiple endocrine neoplasia type 1. In: DeGroot LJ, Jameson JL, eds. *Endocrinology: Adult and Pediatric*. 6th ed. Philadelphia: Saunders; 2010:2719-2741.
- Thakker RV. Multiple endocrine neoplasia type 1 (MEN1). In: Robertson R, Thakker RV, eds. *Translational Endocrinology and Metabolism: Neoplasia Update*. Chevy Chase: The Endocrine Society; 2011:13-44.
- Larsson C, Skogseid B, Oberg K, Nakamura Y, Nordenskjöld M. Multiple endocrine neoplasia type 1 gene maps to chromosome 11 and is lost in insulinoma. *Nature*. 1988;332(6159):85-87. [\[CrossRef\]](#)
- Chandrasekharappa SC, Guru SC, Manickam P, et al. Positional cloning of the gene for multiple endocrine neoplasia-type 1. *Science*. 1997;276(5311):404-407. [\[CrossRef\]](#)
- Heppner C, Kester MB, Agarwal SK, et al. Somatic mutation of the MEN-1 gene in parathyroid tumours. *Nat Genet*. 1997;16(4):375-378. [\[CrossRef\]](#)
- Thakker RV, Bouloux P, Wooding C, et al. Association of parathyroid tumors in multiple endocrine neoplasia type 1 with loss of alleles on chromosome 11. *N Engl J Med*. 1989;321(4):218-224. [\[CrossRef\]](#)
- Lemos MC, Thakker RV. Multiple endocrine neoplasia type 1 (MEN1): analysis of 1336 mutations reported in the first decade following identification of the gene. *Hum Mutat*. 2008;29(1):22-32. [\[CrossRef\]](#)
- Marini F, Cianferotti L, Giusti F, Brandi ML. Molecular genetics in primary hyperparathyroidism: the role of genetic tests in differential diagnosis, disease prevention strategy, and therapeutic planning. A 2017 update. *Clin Cases Miner Bone Metab*. 2017;14(1):60-70. [\[CrossRef\]](#)
- Vierhapper H, Rondot S, Schulze E, et al. Primary hyperparathyroidism as the leading symptom in a patient with a Y791F RET mutation. *Thyroid*. 2005;15(11):1303-1308. [\[CrossRef\]](#)
- Richards S, Aziz N, Bale S, et al. Standards and guidelines for the interpretation of sequence variants: a joint consensus recommendation of the American College of Medical Genetics and Genomics and the Association for Molecular Pathology. *Genet Med*. 2015;17(5):405-424. [\[CrossRef\]](#)
- Eller-Vainicher C, Chiodini I, Battista C, et al. Sporadic and MEN-1-related primary hyperparathyroidism: differences in clinical expression and severity. *J Bone Miner Res*. 2009;24(8):1404-1410. [\[CrossRef\]](#)
- Eastell R, Arnold A, Brandi ML, et al. Diagnosis of asymptomatic primary hyperparathyroidism: proceedings of the third international workshop. *Proceedings of the Third International Workshop. J Clin Endocrinol Metab*. 2009;94(2):340-350. [\[CrossRef\]](#)
- Newey PJ, Thakker RV. Role of multiple endocrine neoplasia type 1 mutational analysis in clinical practice. *Endocr Pract*. 2011;17(suppl 3):8-17. [\[CrossRef\]](#)
- Goudet P, Murat A, Binquet C, et al. Risk factors and causes of death in MEN1 disease. A GTE (Groupe d'Etude des Tumeurs Endocrines) cohort study among 758 patients. *World J Surg*. 2010;34(2):249-255. [\[CrossRef\]](#)
- Dean PG, van Heerden JA, Farley DR, et al. Are patients with multiple endocrine neoplasia type I prone to premature death? *World J Surg*. 2000;24(11):1437-1441. [\[CrossRef\]](#)
- The UMD-MEN1 Mutations. Available at: <http://www.umd.be/MEN1/>. Accessed 18 June 2021.
- Romanet P, Mohamed A, Giraud S, et al. UMD-MEN1 database: an overview of the 370 MEN1 variants present in 1676 patients from the French population. *J Clin Endocrinol Metab*. 2019;104(3):753-764. [\[CrossRef\]](#)
- Bassett JHD, Forbes SA, Pannett AAJ, et al. Characterization of mutations in patients with multiple endocrine neoplasia type 1. *Am J Hum Genet*. 1998;62(2):232-244. [\[CrossRef\]](#)
- Kouvaraki MA, Lee JE, Shapiro SE, et al. Genotype-phenotype analysis in multiple endocrine neoplasia type 1. *Arch Surg*. 2002;137(6):641-647. [\[CrossRef\]](#)

25. Agarwal SK, Mateo CM, Marx SJ. Rare germline mutations in cyclin-dependent kinase inhibitor genes in multiple endocrine neoplasia type 1 and related states. *J Clin Endocrinol Metab.* 2009;94(5):1826-1834. [\[CrossRef\]](#)
26. Belar O, De La Hoz C, Pérez-Nanclares G, Castaño L, Gaztambide S, Spanish MEN1 Group. Novel mutations in MEN-1, CDKN1B and AIP genes in patients with multiple endocrine neoplasia type 1 syndrome in Spain. *Clin Endocrinol (Oxf).* 2012;76(5):719-724. [\[CrossRef\]](#)
27. Turner JJ, Christie PT, Pearce SH, Turnpenny PD, Thakker RV. Diagnostic challenges due to phenocopies: lessons from Multiple Endocrine Neoplasia type1 (MEN1). *Hum Mutat.* 2010;31(1):E1089-E1101. [\[CrossRef\]](#)
28. Rizzoli R, Green J 3rd, Marx SJ. Primary hyperparathyroidism in familial multiple endocrine neoplasia type I. Long-term follow-up of serum calcium levels after parathyroidectomy. *Am J Med.* 1985;78(3):467-474. [\[CrossRef\]](#)
29. Powell AC, Alexander HR, Pingpank JF, et al. The utility of routine transcervical thymectomy for multiple endocrine neoplasia 1-related hyperparathyroidism. *Surgery.* 2008;144(6):878-884. [\[CrossRef\]](#)
30. Burgess JR, Shepherd JJ, Parameswaran V, Hoffman L, Greenaway TM. Spectrum of pituitary disease in multiple endocrine neoplasia type 1 (MEN 1): clinical, biochemical, and radiological features of pituitary disease in a large MEN 1 kindred. *J Clin Endocrinol Metab.* 1996;81(7):2642-2646. [\[CrossRef\]](#)
31. Vergès B, Boureille F, Goudet P, et al. Pituitary disease in MEN type 1 (MEN1): data from the France-Belgium MEN1 multicenter study. *J Clin Endocrinol Metab.* 2002;87(2):457-465. [\[CrossRef\]](#)
32. Thomas-Marques L, Murat A, Delemer B, et al. Prospective endoscopic ultrasonographic evaluation of the frequency of nonfunctioning pancreaticoduodenal endocrine tumors in patients with multiple endocrine neoplasia type 1. *Am J Gastroenterol.* 2006;101(2):266-273. [\[CrossRef\]](#)
33. Triponez F, Dosseh D, Goudet P, et al. Epidemiology data on 108 MEN 1 patients from the GTE with isolated nonfunctioning tumors of the pancreas. *Ann Surg.* 2006;243(2):265-272. [\[CrossRef\]](#)
34. Kouvaraki MA, Shapiro SE, Cote GJ, et al. Management of pancreatic endocrine tumors in multiple endocrine neoplasia type 1. *World J Surg.* 2006;30(5):643-653. [\[CrossRef\]](#)
35. Wamsteker EJ, Gauger PG, Thompson NW, Scheiman JM. EUS detection of pancreatic endocrine tumors in asymptomatic patients with type 1 multiple endocrine neoplasia. *Gastrointest Endosc.* 2003;58(4):531-535. [\[CrossRef\]](#)
36. Skandarajah A, Barlier A, Morlet-Barlat N, et al. Should routine analysis of the MEN-1 gene be performed in all patients with primary hyperparathyroidism under 40 years of age? *World J Surg.* 2010;34(6):1294-1298. [\[CrossRef\]](#)