



Coexistence of Thyroglossal Duct Papillary Carcinoma and Thyroid Papillary Microcarcinoma

Tiroglossal Kanal Kisti Papiller Karsinomu ve Tiroid Papiller Mikrokarzinom Birlikteliği

Başak Karbek, Mustafa Şahin*, Nujen Bozkurt Çolak, Oya Topaloğlu, Erman Çakal, Murat Karasen**, Tuncay Delibaşı

Dişkapi Yıldırım Beyazıt Training and Research Hospital, Clinic of Endocrinology, Ankara, Turkey

*Ankara University Faculty of Medicine, Department of Endocrinology, Ankara, Turkey

**Keçiören Training and Research Hospital, Clinic of Endocrinology, Ankara, Turkey

Abstract

Malignant lesion of a thyroglossal duct cyst (TGDC) is an extremely rare entity. Papillary carcinoma is the most common malignancy of the endocrine system. Diagnosis is commonly made after pathological examination of the surgical specimen. A 41-year-old male patient with a midline neck mass was initially diagnosed with a thyroglossal duct cyst and underwent a Sistrunk's procedure. Histopathologic examination revealed a papillary thyroid carcinoma within the thyroglossal duct cyst. Ultrasound elastography of the thyroid gland was performed. We have detected a hypoechoic hypervascular thyroid nodule measuring 3 mm in diameter that appeared completely blue in B-mode ultrasonography, and hard tissue was visualized by elastosonography (ES). The patient then underwent total thyroidectomy and bilateral neck dissection. The final pathological finding showed papillary microcarcinoma of the thyroid gland without cervical lymph node metastasis. When a thyroglossal duct cyst is excised using Sistrunk's procedure and when the definitive histological analysis depicts malignancy, the thyroid gland must be studied carefully with radiological examinations. *Turk Jem* 2013; 17: 127-128

Key words: Thyroglossal duct cyst, thyroid papillary carcinoma, hypervascular nodule

Özet

Tiroglossal kanal kistinde karsinom gelişimi oldukça nadirdir. Malign patolojilerin çoğu tiroidin papiller karsinomudur. Tanı, genellikle cerrahi sonrası çıkarılan dokunun histopatolojik incelemesi sonucunda konur. Boyun orta hatta kitlesi olan 41 yaşında erkek hasta başlangıçta tiroglossal duktus kisti tanısıyla Sistrunk ameliyatı oldu, histopatolojik inceleme sonucunda tiroglossal duktus kisti içinde tiroid papiller karsinomu tespit edildi. Tiroid Ultrasonografi ve Elastografi yapıldı. Elastosonografi ile sert, B-mode 'da tamamen mavi görülen 3 milimetre boyutunda hipervasküler tiroid nodülü tespit ettik. Sonrasında hastaya total tiroidektomi, bilateral boyun diseksiyonu yapıldı. Patolojisi, servikal lenf nodu metastazı olmaksızın, tiroid papiller mikrokarsinomu olarak rapor edildi. Tiroglossal kanal kistine yönelik yapılan Sistrunk ameliyatı sonrası histopatolojik inceleme sonucu, malignite olarak tespit edildiğinde, tiroid bezi radyolojik yöntemlerle dikkatle değerlendirilmelidir. *Turk Jem* 2013; 17: 127-128

Anahtar kelimeler: Tiroglossal kanal kisti, tiroid papiller kanser, hipervasküler nodül

Introduction

Thyroglossal duct cyst, a congenital anomaly of the thyroglossal duct residual, is seen in 7% of the young adult population (1). Carcinoma development in thyroglossal duct cyst is quite rare and it is observed in less than 1% of patients (2,3). The most common malignant pathology is the papillary carcinoma of the thyroid (4). Diagnosis is usually made after pathological examination of surgically removed tissue. We planned to present a case who had undergone surgery with the diagnosis of thyroglossal duct cyst while its histopathology was reported as papillary carcinoma; yet after our studies, we detect micropapillary cancer of the thyroid.

Case

A forty-one year old male patient was admitted to the ear-nose-throat outpatient clinic with the complaint of painless palpable swelling that he noticed three months ago. On physical examination; a 2x2cm palpable mass was found on neck midline between thyroid cartilage and hyoid bone. Patient had no history of radiation to the neck, and he was clinically euthyroid. The ultrasound performed on the neck by Radiology; a 20x15 mm irregular cystic mass lesion containing solid component was seen adjacent to the right lateral superior of the hyoid bone. The thyroid gland size was normal and its contour was smooth. The thyroid gland had homogeneous echo pattern and no lesion was detected, which made difference in the

eco of the gland. Patient was scheduled for the excision of the mass and in the preoperative neck cranial computed tomography, in a similar way, a 19x13 mm lobulated hypodense mass was seen in the anterosuperior of the hyoid bone. There was neither pathological lymph node in size and appearance nor space-occupying lesion in the thyroid gland. The Tc-99m thyroid scintigraphy result was normal. Patient had Sistrunk operation in otolaryngology clinic. The result of histopathological examination was reported as papillary carcinoma arising from thyroglossal duct and with the aim of further examination the patient was directed to the endocrinology department. In the thyroid ultrasound performed in our clinic, a 2x3x3 mm hypoechoic lesion was detected in the right lobe close to the isthmus (Figure 1). Lesions' elastography score was measured as 4, and its strain index was 2.67 (Figure 2). We did a fine-needle aspiration from the lesion and the result was reported as 'papillary carcinoma'. Total thyroidectomy and anterior neck dissection was performed. In the histopathological evaluation; 2 papillary carcinoma lesions were detected which were 4 mm and 2 mm in diameter. Among evaluated 20 lymph nodes and thyroglossal remnant, no tumor was reported.

Discussion

The finding of mass in the neck is a common clinical finding and thus numerous pathologies should be considered in differential diagnosis. Most of the masses are benign but malignant diseases should not be ignored. Therefore, it is important to develop a systematic approach towards a patient who has a mass in the neck. Benign thyroglossal channel cysts are often detected as front neck masses which are asymptomatic, soft and has no tend to grow. Carcinoma development in thyroglossal duct cyst is quite rare and it is observed in less than 1% of patients (2,3). Because of this rarity, we do not usually suspect of malignancy prior to surgical excision. However, as in our case, in the presence of a mass that is fixed and rapidly increasing in size, physicians may suspect of malignancy. Older patients, female patients, and patients with the rapid growth of the lesion are more at risk in terms of malignancy (5). In Carcinomas arising from the thyroglossal duct cyst, two histological origins have been described. First and more frequent is thyroid elements and the second is carcinomas developed from squamous cell epithelial. The most common cancer seen in thyroglossal cysts is papillary carcinoma, as in our case (85%). Because of the carcinoma development in thyroglossal duct cyst is very rare, prior to surgery clinicians usually do not suspect of an oncologic diagnosis and as a result thyroglossal duct cyst carcinoma diagnosis is made by histopathological examination of samples after surgery. To overcome this difficulty, in patients who got diagnosed with thyroglossal duct cysts, neck lymph nodes and thyroid gland need to be examined in detail. In our case, the preoperative thyroid gland assessment was made by the radiology department, but 3 mm hypoechoic nodule could not be detected neither in ultrasound nor in scintigraphy. Elastasonography's (ES) use for the diagnostic approach to thyroid nodules has become widespread in recent years. SI values determined by ESR, combined with the characteristics of the nodule using ultrasound is a non-invasive, advantageous method in the differential diagnosis of thyroid nodules (8). In the literature, two more case reports are available with both papillary carcinoma in the thyroid gland and papillary carcinoma in thyroglossal duct cyst

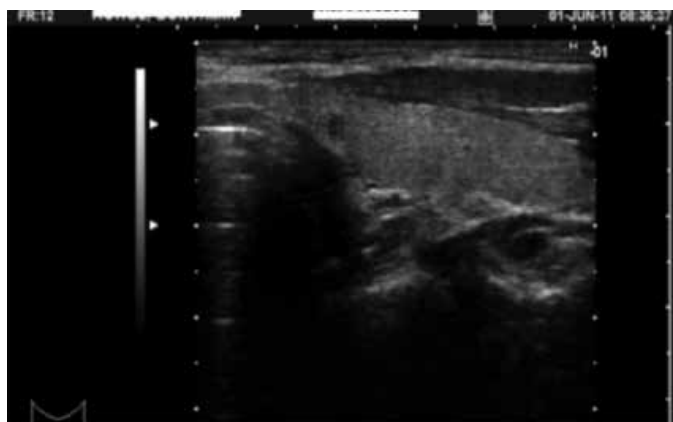


Figure 1. Thyroid ultrasound image

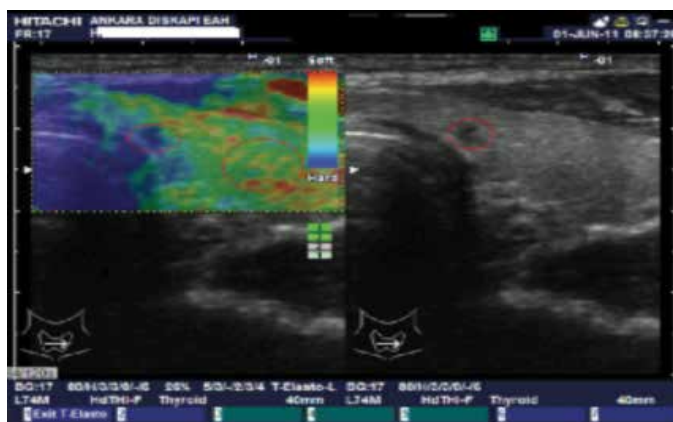


Figure 2. Nodules elastasonographic image

without pathologic lymph node in the neck (6,7). Therefore, in cases of thyroglossal duct cyst, even with a very little risk of malignancy, the probability of papillary microcarcinoma in thyroid gland should be considered. We think that this is due to the thyroglossal duct thyroid microcarcinoma metastasis or multifocality of the papillary thyroid carcinoma in two separate regions as a result of the same mutation. The detailed evaluation of thyroid gland and lymph nodes is crucial to determine the type of operation that will be performed on the patient.

References

1. Vincent S, Synhorst II J. Adenocarcinoma arising in a thyroglossal duct cyst. *J. Oral Maxillofac Surg* 1989;47:633-5.
2. Allard R. The thyroglossal cyst. *Head Neck Surg* 1982;5:134-46.
3. Fernandez J, Ordonez N, Shultz P, Samaan N, Hickey R. Thyroglossal duct carcinoma. *Surgery* 1991;110:928-35.
4. Van Vuuren PA, Balm AJ, Gregor RT, Hilgers FJ, Loftus BM, Delprat CC, et al. Carcinoma arising in thyroglossal remnants. *Clin Otolaryngol Allied Sci* 1994;19:509-15.
5. Topf P, Fried M, Strome M. Vagaries of thyroglossal duct cysts. *Laryngoscope* 1988; 98:40-2.
6. Park MH, Yoon JH, Jegal YJ, Lee JS. Papillary thyroglossal duct cyst carcinoma with synchronous occult papillary thyroid microcarcinoma. *Yonsei Med J* 2010;51:609-11.
7. Kandogan T, Erkan N, Vardar E. Papillary carcinoma arising in a thyroglossal duct cyst with associated microcarcinoma of the thyroid and without cervical lymph node metastasis: a case report. *J Med Case Reports* 2008;2:42.
8. Xing P, Wu L, Zhang C, et al. Differentiation of benign from malignant thyroid lesions: calculation of the strain ratio on thyroid sonoelastography. *J Ultrasound Med* 2011;30:663-9.