



# Diabetes Insipidus and Anterior Pituitary Insufficiency Due to Breast Cancer Metastasis

## Meme Kanseri Metastazına Bağlı Gelişen Diabetes Insipidus ve Ön Hipofiz Yetmezliği Olgusu

Ayşe Arduç, Ayşe Gül Alımlı\*, Berçem Ayçiçek Doğan, Mazhar Müslüm Tuna, Dilek Berker, Serdar Güler\*\*

Ankara Numune Research and Training Hospital, Clinic of Endocrinology and Metabolism, Ankara, Turkey

\*Gazi University Faculty of Medicine, Department of Radiology, Ankara, Turkey

\*\*Hitit University Faculty of Medicine, Department of Endocrinology and Metabolism, Çorum, Turkey

### Abstract

Metastases from breast cancer to the pituitary gland are uncommon. We present a 35-year-old woman with diabetes insipidus and anterior pituitary insufficiency resulting from breast cancer metastases to the pituitary gland. The patient presented with reduced consciousness, fatigue, polyuria, and polydipsia. Hypernatremia (sodium: 154 mmol/L), hypostenuria (urine density: 1001), and hypopituitarism were present on laboratory evaluation. Magnetic resonance imaging (MRI) revealed heterogeneous pituitary gland, thickened pituitary stalk (8mm), and loss of normal hyperintense signal of the posterior pituitary. Based on the clinical, laboratory, and MRI findings, the patient was diagnosed with diabetes insipidus and anterior pituitary insufficiency due to pituitary metastases from breast cancer. She received desmopressin, L-thyroxine, and prednisolone, which resulted in improvement of her symptoms and laboratory results. The patient, who also received Gamma Knife radiosurgery and chemotherapy, died six months later due to disseminated metastases. Although pituitary metastasis is rare, it should be kept in mind in patients with breast cancer since early detection and treatment can improve symptoms of patients.

**Keywords:** Breast cancer metastasis, diabetes insipidus, anterior hypopituitarism

### Öz

Hipofiz bezine meme kanseri metastazı olgusu nadir görülen bir durumdur. Hipofiz metastazına bağlı diabetes insipidus ve ön hipofiz yetmezliği gelişen 35 yaşındaki meme kanserli kadın olguyu sunduk. Hasta bilinç bulanıklığı, halsizlik, çok su içme ve sık idrara gitme şikayetleri ile başvurdu. Laboratuvar incelemelerinde hipernatremi (plazma sodyum:154 mmol/L), hipostenüri (idrar dansitesi: 1001) ve hipopituitarizm saptandı. Hipofiz manyetik rezonans (MR) görüntülemesinde hipofiz bezinde heterojenite, infundibulumda kalınlaşma (8 mm), posterior hipofizin hiperintens özelliğini kaybettiği görüldü. Klinik, laboratuvar ve MR bulguları nedeniyle hastaya hipofiz metastazına bağlı diabetes insipidus ve ön hipofiz yetmezliği tanısı konuldu. Desmopressin, prednisolon ve levotiroksin tedavileri ile hastanın semptomlarında ve laboratuvar bulgularında düzelme saptandı. Gamma Knife radyo cerrahi ve kemoterapi de uygulanan hasta yaygın metastazlar nedeniyle 6 ay sonra öldü. Erken tanı ve tedavinin hasta semptomlarında belirgin iyileşme sağlaması nedeni ile hipofiz bezi metastazları nadir görülseler de meme kanserli hastalarda akıldan tutulmalıdır.

**Anahtar kelimeler:** Meme kanseri metastazı, diabetes insipidus, ön hipofiz yetmezliği

### Introduction

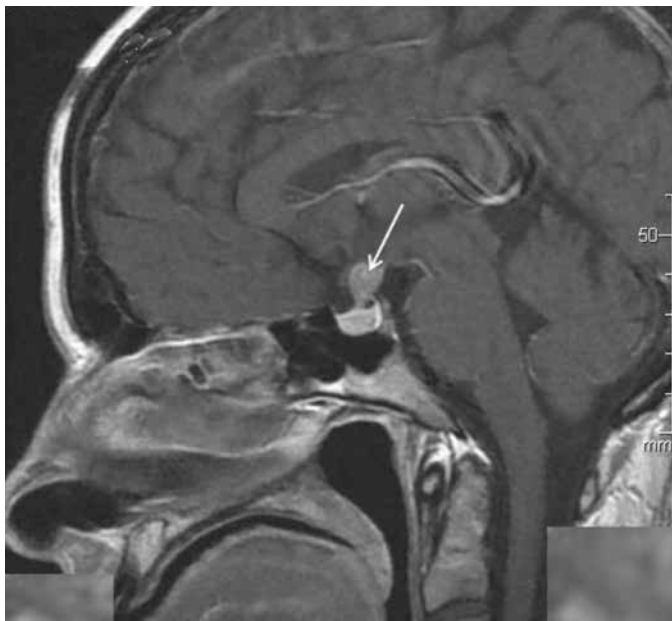
Pituitary metastases (PMs) from various malignancies are relatively rare clinical conditions occurring in 1-3% of cancer patients, and accounting for only 1% of resected pituitary tumors (1). Breast and lung cancers are the most common type of cancers to metastasize to the pituitary gland. In one case series, metastases from breast cancer and lung cancer accounted for 33% and 36% of PMs, respectively (2). Prostate, renal, thyroid, and gastrointestinal cancers, and hematologic malignancies have also been reported to be associated with PM (3). The majority of PM is clinically silent with one series showing that 7% were symptomatic (4). In symptomatic patients,

diabetes insipidus (DI) due to posterior lobe involvement is the most common clinical presentation, and headache, visual symptoms, and ophthalmoplegia can also occur (2). A hypofunction of the anterior lobe alone or both anterior and posterior lobe hypofunctions are relatively rare. We, herein, present the case of a 35-year-old woman suffering from breast cancer, who developed both DI and anterior hypopituitarism two years after the initial diagnosis of breast cancer.

### Case Report

A 35-year-old woman presented with a gradually decreasing level of consciousness starting one day before the admission.

The patient reported generalized fatigue, nausea, polyuria, and polydipsia for the past two weeks. She was drinking about 5 liters of water with a daily urine output of 5.5 liter. She had been diagnosed with infiltrating ductal adenocarcinoma of the right breast (estrogen receptor and progesterone receptor positive), and had right mastectomy followed by chemotherapy (taxotere, epirubicin) and hormone therapy (tamoxifen) two years previously. One year after right mastectomy, she had left mastectomy and she was given chemotherapy (cisplatin, navelbine, trastuzumab, lapatinib, and letrozole), tamoxifen, and radiotherapy because of the relapsed breast cancer in the contralateral breast. She was taking only tamoxifen for the past three months. On physical examination, blood pressure was 100/60 mmHg, pulse 90/min. Her consciousness was reduced with no other remarkable finding on neurological examination. Laboratory test results revealed that she had hypernatremia and hyposthenuria (plasma sodium: 154 mmol/L, urine density: 1001) (Table 1). On admission, a magnetic resonance imaging (MRI) of the pituitary region (Figure 1) revealed heterogeneous appearance of the pituitary gland with heterogeneous contrast uptake, thickening of the pituitary infundibulum (8 mm) with enhancement after the injection of contrast agent, and a loss of the normal hyperintense signal of the posterior pituitary on T1-weighted images. Although fluid restriction test could not be performed due to cognitive impairment, central DI was diagnosed based on the clinical signs (polydipsia, polyuria), negative water balance, low urine density, high plasma osmolality in relation with a very low urine osmolality (315 mOsm/kg and 110 mOsm/kg, respectively), and MRI findings. After she was given desmopressin nasal spray (10 µg twice daily), the symptoms of nausea, polyuria, and polydipsia disappeared and hypernatremia resolved. As shown in Table 1, hormonal evaluation revealed anterior hypopituitarism and



**Figure 1.** Sagittal view of T1 weighted magnetic resonance images of pituitary region after the injection of gadolinium shows heterogeneity of pituitary gland and enlargement of pituitary infundibulum. White arrow shows enlargement of pituitary infundibulum

hyperprolactinemia. She was treated with L-thyroxine (100 µg/day) and prednisolone (7.5 mg/day in divided doses morning and afternoon). Soon after the onset of the treatment, she reported a gradual resolution of her fatigue. Imaging studies showed liver and vertebrae metastases with multiple involvement. She underwent Gamma Knife radiosurgery and chemotherapy. The patient needed ongoing medical treatment for DI and hypopituitarism after these treatments. Because of breast cancer progression, she died six months later.

## Discussion

Breast cancer is one of the most common cancers. Bones, liver, and lungs are the typical sites for metastasis in breast cancer patients whereas the pituitary gland is rarely affected (5). One

**Table 1. Laboratory findings of the patient**

Measurement	p	Normal limits
Fasting blood glucose, mg/dL (70-100 mg/dL)	80	70-100
Urea, mg/dL (5-20 mg/dL)	13	10-50
Creatinine, mg/dL (0.6-1.3 mg/dL)	1	0.44-1.03
Plasma osmolality, mOsm/kg	315	280-295
Urine osmolality, mOsm/kg	110	400-800
Urine density	1001	1015-1025
Sodium, mmol/L (136-144/3.5-5.1 mmol/L)	154	135-145
Potassium, mmol/L	4.2	3.5-5.5
Alanine aminotransferase, U/L (10-40 IU/mL)	84	5-50
Hemoglobin, g/dL (14-17.5 g/dL)	13.3	12.3-15.3
ACTH, pg/mL	6.4	4.7-48.8
Morning plasma cortisol, µg/dL	5.3	10-22.6
Insulin-induced hypoglycemia test plasma cortisol, µg/dL cortisol	12	≥18 µg/dL
TSH, uIU/mL	1.88	0.34-5.60
Free Thyroxine, ng/dL	0.50	0.61-1.48
FSH, mIU/mL	3.6	3.85-8.78
LH, mIU/mL (10.87-58.64 mIU/mL)	0.8	2.12-10.89
Estradiol, pg/mL (<20-40 pg/mL)	15	27-122
Prolactin, ng/mL (2.74-19.64 ng/mL)	95.9	3.3-26.7
Growth hormone, ng/mL	<0.1	0.1-4.77
IGF-1, ng/mL	59	115-307

ACTH: Adrenocorticotrophic hormone, FSH: Follicle-stimulating hormone, LH: Luteinizing hormone, TSH: Thyroid stimulating hormone

study revealed that 0.9% of patients had PM five years after the diagnosis of the breast cancer (6). Therefore, our patient demonstrates a rare pattern of breast cancer metastasis.

PM resulting from breast cancer is more common in elderly patients with widespread disease (2), as in our patient with multiple liver and bone metastases. Hormone receptor status of the breast tumor does not seem to influence the risk of PM (2). The most important path for the development of PM is hematogenous spread. The posterior lobe is the most affected site due to rich blood supply through the hypophyseal arteries. In one autopsy series including 88 patients with PM, the posterior lobe was involved in almost 70% of cases, anterior lobe in 13%, both anterior and posterior lobes in 12%, and infundibulum in 5% (4). Therefore, the main clinical symptoms are polyuria, nocturia, and polydipsia due to DI in most cases. If the patients with DI have intact thirst mechanism and free access to oral fluids, they may not present with hypernatremia (7). In addition to DI, laboratory results of our patient demonstrated a central hypothyroidism, hypocortisolism, hypogonadism, and low IGF-1 levels, which was consistent with anterior pituitary insufficiency. Hyperprolactinemia seen in our case was most consistent with disconnection hyperprolactinemia due to stalk metastasis. Although the diagnosis of PM was not confirmed by biopsy in our case, MRI findings (inhomogeneous pituitary gland, thickening of the infundibulum, loss of normal hyperintense signal of the posterior pituitary) and the presence of advanced breast cancer were suggestive of PM (8,9).

The treatment modalities for PM are surgery, radiotherapy, and systemic treatment with endocrine therapy or chemotherapy (10,11). Surgery is usually palliative. A hormone substitution with desmopressin for DI and pituitary hormone replacement treatment for anterior pituitary insufficiency are usually needed, and these treatments improve quality of life substantially, as seen in our case. Radiotherapy and Gamma Knife radiosurgery are also good options for relief of symptoms (12,13). Chemotherapy combined with radiotherapy is preferred in patients with diffuse malignant disease. Our patient required ongoing treatment for DI and hypopituitarism after treatments with Gamma Knife radiosurgery and chemotherapy. Breast cancer patients with PM have poor prognosis with a median survival time of six months, as was in our case. Multiple metastases, short period between diagnosis of the primary and secondary tumor, older age at the time of diagnosis are worse prognostic factors (2,14).

## Conclusion

Although the pituitary gland is a less common site for breast cancer metastasis, it should be considered in patients with

metastatic disease who are diagnosed with DI and, in rare cases, anterior pituitary insufficiency. Although patients with PM have poor prognosis, early detection and pituitary hormone replacement therapy can provide improvement in the symptoms of patients.

## Ethics

*Informed Consent: Consent form was filled out by all participants, Peer-review: Externally peer-reviewed.*

## Authorship Contributions

*Concept: Ayşe Arduç, Design: Ayşe Arduç, Data Collection or Processing: Ayşe Arduç, Berçem Ayçiçek Doğan, Mazhar Müslüm Tuna, Analysis or Interpretation: Ayşe Gül Alımlı, Dilek Berker, Serdar Güler, Writing: Ayşe Arduç, Ayşe Gül Alımlı, Conflict of Interest: The authors declare no conflicting interests, Financial Disclosure: The authors have nothing to disclose.*

## References

1. Fassett DR, Couldwell WT. Metastases to the pituitary gland. *Neurosurg Focus* 2004;16:8.
2. Morita A, Meyer FB, Laws ER Jr. Symptomatic pituitary metastases. *J Neurosurg* 1998;89:69-73.
3. Weil RJ. Pituitary metastasis. *Arch Neurol* 2002;59:1962-1963.
4. Teeb RS, Silverman EM. Clinicopathologic review of 88 cases of carcinoma metastatic to the pituitary gland. *Cancer* 1975;36:216-220.
5. Saphner T, Tormey DC, Gray R. Annual hazard rates of recurrence for breast cancer after primary therapy. *J Clin Oncol* 1996;14:2738-2746.
6. Yap HY, Tashima CK, Blumenschein GR, Eckles N. Diabetes insipidus and breast cancer. *Arch Intern Med* 1979;139:1009-1011.
7. Robertson GL. Diabetes insipidus. *Endocrinol Metab Clin North Am* 1995;24:549-72.
8. Mayr NA, Yuh WT, Muhonen MG, Koci TM, Tali ET, Nguyen HD, Bergman RA, Jinkins JR. Pituitary metastases: MR findings. *J Comput Assist Tomogr* 1993;17:432-437.
9. Chaudhuri R, Twelves C, Cox TC, Bingham JB. MRI in diabetes insipidus due to metastatic breast carcinoma. *Clin Radiol* 1992;46:184-188.
10. Gormally JF, Izard MA, Robinson BG, Boyle FM. Pituitary metastasis from breast cancer presenting as diabetes insipidus. *BMJ Case Rep* 2014;2014.
11. Pagani O, Senkus E, Wood W, Colleoni M, Cufer T, Kyriakides S, Costa A, Winer EP, Cardoso F; ESO-MBC Task Force. International guidelines for management of metastatic breast cancer: Can metastatic breast cancer be cured? *J Natl Cancer Inst* 2010;102:456-463.
12. Iwai Y, Yamanaka K, Honda Y, Matsusaka Y. Radiosurgery for pituitary metastases. *Neurol Med Chir (Tokyo)* 2004;44:112-116.
13. Piedra MP, Brown PD, Carpenter PC, Link MJ. Resolution of diabetes insipidus following gamma knife surgery for a solitary metastasis to the pituitary stalk. Case report. *J Neurosurg* 2004;101:1053-1056.
14. Niyonga-Pono MP, Thomopoulos P, Luton JP. Pituitary metastases. 3 cases. *Presse Med* 1999;28:1567-1571.