



Parathyroid Adenoma, Gastric Adenocarcinoma, and Intraabdominal Schwannoma in One Patient

Bir Hastada Paratiroid Adenom, Mide Adenokarsinom ve İntraabdominal Schwannom Birlikteliği

Gülşah Elbüken, Ersin Ergün*, Özlem Öztürk**, Erdoğan Selçuk Şeber***, Mücahit Doğru****, Ülkü Korkmaz*****

Tekirdağ State Hospital, Clinic of Endocrinology and Metabolism, Tekirdağ, Turkey

*Tekirdağ Government Hospital, Clinic of General Surgery, Tekirdağ, Turkey

**Tekirdağ Government Hospital, Clinic of Pathology, Tekirdağ, Turkey

***Tekirdağ Government Hospital, Clinic of Medical Oncology, Tekirdağ, Turkey

****Tekirdağ Government Hospital, Clinic of Radiology, Tekirdağ, Turkey

*****Tekirdağ Government Hospital, Clinic of Nuclear Medicine, Tekirdağ, Turkey

Abstract

Intraabdominal schwannomas, which occur quite rarely, are usually benign tumors. They are often discovered coincidentally when abdominal scans are performed for other reasons. We also coincidentally detected an intraabdominal schwannoma in addition to primary hyperparathyroidism related to a parathyroid adenoma and a gastric adenoma which caused partial pyloric obstruction in a 69-year-old female patient who was admitted to our emergency room with vomiting while we were further investigating hypercalcemia that was found during laboratory workup. It is rare to diagnose multiple tumors concurrently in a single patient which are components of certain neuroendocrine syndromes themselves. It is more interesting to see a rare tumor such as intraabdominal schwannoma coexisting with a parathyroid adenoma that can be a component of multiple endocrine neoplasia syndromes. In the literature, there are few case reports of the coexistence of intraabdominal schwannomas with adenocarcinoma of the gastrointestinal tract. Here, we present an unusual case of intraabdominal schwannoma coexisting with parathyroid adenoma and gastric adenocarcinoma, all diagnosed in a single patient. To our best knowledge, this is the first case report of such a rare coexistence which makes it rather interesting.

Keywords: Parathyroid adenoma, intraabdominal schwannoma, gastric adenocarcinoma, primary hyperparathyroidism

Öz

İntraabdominal schwannomlar oldukça nadir rastlanan, genellikle benign seyirli tümörlerdir. Tanıları genellikle yapılmış olan abdominal görüntülemeler sonrasında tesadüfen konulmaktadır. Biz de kusma şikayetleri ile acil servisimize başvurmuş olan 69 yaşında bir kadın hastada tespit edilen hiperkalsemiyi araştırırken, paratiroid adenomuna bağlı primer hiperparatiroidi ve kısmi pilor obstrüksiyonuna yol açmış mide adenokarsinomuyla birlikte, tesadüfen tespit edilen intraabdominal schwannom saptadık. Kendileri başlı başına bazı nöroendokrin sendromların bir komponenti olan bazı tümörlerin tek bir hastada tespit edilmesi nadir bir durumdur. İntraabdominal schwannom gibi nadir bir tümörün, multipl endokrin neoplazi sendromlarının bir komponenti olabilen paratiroid adenomuyla birlikte olması daha da ilginç bir durumdur. Ayrıca intraabdominal schwannomlarla birlikte görülen, gastrointestinal sistem kaynaklı adenokarsinom birliktelikleri ile ilgili az sayıda olgu bildirimleri vardır. Biz de paratiroid adenom, mide adenokarsinom ve intraabdominal schwannom birlikteliği gösteren bir olguyu sunmayı uygun bulduk. Bildiğimiz kadarıyla literatürde bu üç tümörü tek hastada barındıran tek olgudur ve bu sebeple de bu durum olgumuzu ilgi çekici kılmaktadır.

Anahtar kelimeler: Paratiroid adenomu, intraabdominal schwannom, mide adenokarsinomu, primer hiperparatiroidi

Introduction

Concurrent development of tumors that secrete different hormones in a single patient is common in endocrinology practice (1,2,3,4). Coexistence of several tumors may be the result of mutations or defects in some genes and run in a family and it can also occur sporadically. Such tumors may be a component of certain familial

neuroendocrine tumor syndromes. Loss of function in some genes is thought to play a role in the pathogenesis of these syndromes (4,5). For example, parathyroid, pituitary, and pancreatic tumors are predominant in multiple endocrine neoplasia type 1 (MEN 1); and medullary thyroid carcinoma, parathyroid adenoma, and pheochromocytomas are common in MEN type 2A and 2B (MEN 2A and MEN 2B) (6,7). Furthermore, neurofibromatosis

Address for Correspondence: Gülşah Elbüken MD, Tekirdağ State Hospital, Clinic of Endocrinology and Metabolism, Tekirdağ, Turkey

Phone: +90 282 262 53 55 E-mail: gelbuen@yahoo.com.tr **Received:** 12/04/2015 **Accepted:** 04/09/2015

Turkish Journal of Endocrinology and Metabolism, published by Galenos Publishing.

This article is distributed under the terms of the "Creative Commons Attribution NonCommercial 4.0 International Licence (CC BY-NC 4.0)".

type 1 (NF 1) is frequently associated with gastrointestinal stromal tumor (GIST), pheochromocytoma, breast cancer, leukemia, optic glioma, malignant peripheral nerve sheath tumors, and benign skin findings. Vestibular schwannomas, meningiomas, ependymomas, and astrocytomas are also more common in NF type 2 (NF 2). NF are a group of three genetically distinct disorders that cause tumors to grow in the nervous system. Other than NF 1 and NF 2, there is a third type of NF called "schwannomatosis" which was formerly considered as a variation of NF 2 and later characterized as a separate group. A distinctive feature of schwannomatosis that differentiates it from other NF types is the occurrence of multiple schwannomas all over the body in patients in the absence of bilateral vestibular schwannomas. Up to one-third of those patients may have additional tumors in other

body parts such as arms, legs or spine. Diagnosis of all of these genetically inherited disorders is made on the basis of clinical manifestations in the patient as well as one of his/her first degree relatives (8,9).

Case Report

A 69-year-old female patient was admitted to the emergency department at our hospital with a complaint of vomiting. During her laboratory tests, hypercalcemia was detected and she was referred to the endocrinology outpatient clinic. Her past medical history revealed nephrolithiasis and a urinary tract surgery. Physical examination of the patient was unremarkable. Serum calcium, phosphate and parathormone levels were 13 mg/dL, 3 mg/dL, and 410 pg/mL, respectively. Mild hypochromic and microcytic anemia with low ferritin levels was also detected. Her laboratory tests are summarized at Table 1.

Neck ultrasonography revealed a solitary lesion on the right parathyroid region (Figure 1). Dual phase 99mTechnetium sestamibi parathyroid scintigraphy imaging showed an area with increased uptake in the lower right and upper left thyroid

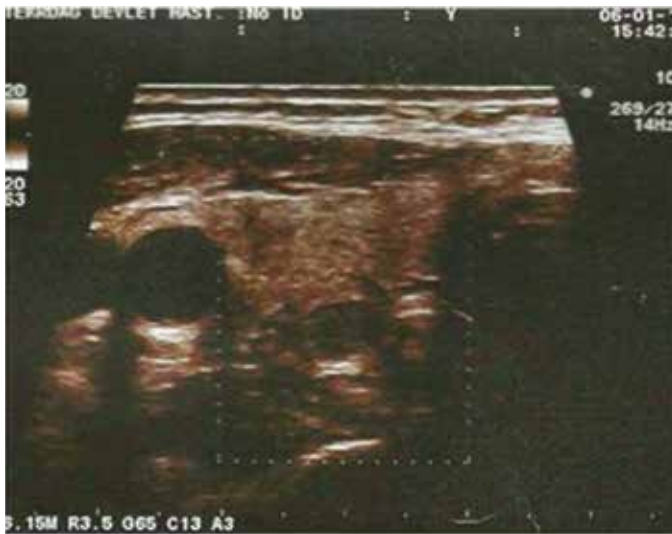

Figure 1. Neck ultrasound shows homogenous hypoechoic solid mass lesion in the inferior of right lobe of thyroid

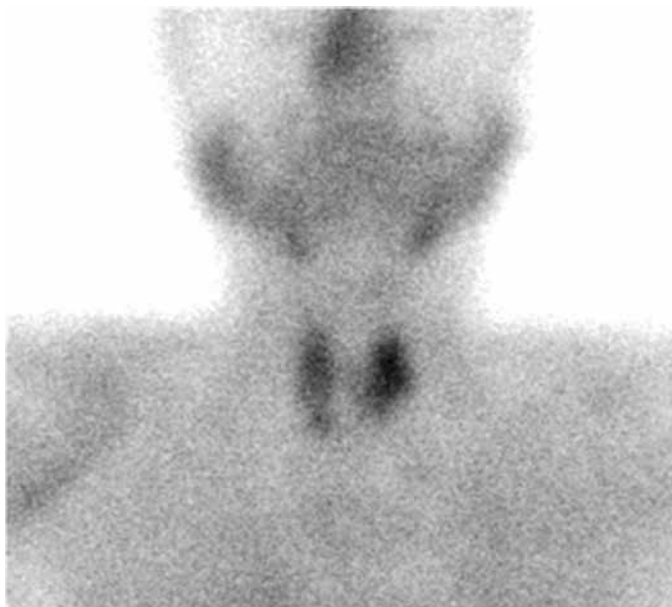

Figure 2. Tc-99m-sestamibi parathyroid scintigraphy of the patient

Table 1. Pre and post-operative biochemical tests of the patient

Parameter	Pre-operative	Post-operative	Reference ranges	Unit
BUN	41	45	10-50	mg/dL
Creatinine	1.2	1.0	0.5-1.0	mg/dL
Calcium	13	8.5	8.6-10.2	mg/dL
Phosphate	3	5.8	3.5-4.5	mg/dL
Albumin	4.3	4.0	3.5-5.2	g/dL
ALP	94	252	<300	U/L
PTH	410	7	20-75	pg/mL
25-OH vitamine D	4	-	30-100	nmol/L
AST	14	36	0-32	U/L
ALT	10	32	0-33	U/L
TSH	0.70	0.74	0.25-5.00	µIU/mL
ft4	1.40	1.20	0.88-1.72	ng/dL
Ferritin	9.9	10.0	7-276.8	ng/mL
Vitamine B12	631	-	214-914	pg/mL
Pholate	24	-	5.38-24	ng/mL
Prolactin	14.3	10	1.9-25	ng/mL
Basal calcitonin	4		Males: <11 Females: <5	pg/mL
CEA	-	1.23	0-3.00	ng/mL
CA 19.9	-	8.7	0-35.0	U/mL

BUN: Blood urea nitrogen, ALP: Alkaline phosphatase, PTH: Parathormone, OH: Hydroxy, AST: Aspartate aminotransferase, ALT: Alanine transaminase, TSH: Thyroid-stimulating hormone, ft₄: Free thyroxine, CEA: Carcinoembryonic antigen, CA: Cancer antigen

lobes (Figure 2). These findings confirmed the diagnosis of primary hyperparathyroidism.

The patient was hospitalized for the treatment of hypercalcemia and treated with intravenous saline infusion and furocemide. An abdominal ultrasound examination revealed a hypoplastic left kidney and a simple parenchymal cystic lesion (57×37 mm) in the right kidney.

Although her serum calcium levels began to decline, clinical findings had not improved. Vomiting was more severe than what would be expected from the clinical findings of hypercalcemia. Thus, gastroscopy was performed due to persistent vomiting after obtaining informed consent from the patient. A solid tumor as well as some ulcers in the antrum which extended to the pyloric region and partially occluding the pyloric canal were seen (Figure 3). Histopathological examination of the tumor revealed a malignant pattern. Since oral feeding of the patient was not possible, total parenteral nutrition was initiated. Abdominal computed tomography, which was performed to determine operability, showed thickening of the gastric wall in the antral region. Additionally, hypoplastic left kidney and a millimetric calculus with mild pelvicalyceal dilatation were detected. Also, a cystic lesion 40 mm in diameter on the right kidney and an

adjacent solid lesion (35×23 mm in size), which seemed to be a malignant lymph node enlargement, were observed (Figure 4).

The patient underwent distal subtotal gastrectomy and Roux-en-Y gastrojejunostomy. After pathological investigation of the surgical specimens, tumor was classified as adenocarcinoma (signet ring cell type) with focal serosal invasion, and metastasis to 4 lymph nodes was detected. Lymphovascular and neural invasion was not detected. Histopathological evaluation of the tumor specimen was consistent with gastric carcinoma grade IIIC (Figure 5). A solid lesion which mimicked a lymph node was removed from the vicinity of the left common iliac artery and reported as a schwannoma (Figure 6). At 4 weeks after gastric surgery, the patient underwent a parathyroidectomy operation and, upper left parathyroid gland and lower parathyroid adenoma were removed. Histopathological examination of the specimen showed normal parathyroid tissues of the left upper parathyroid gland. A specimen from the right parathyroid gland was reported as a parathyroid adenoma. Parathyroid tissues were positively stained for cytokeratin 19 and chromogranin.

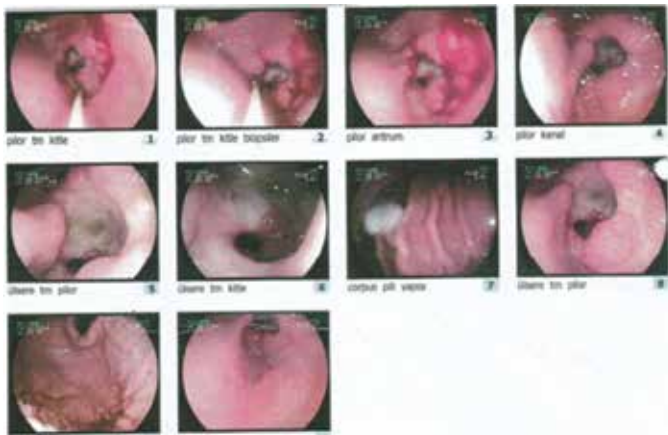

Figure 3. Gastroscopic images of the patient

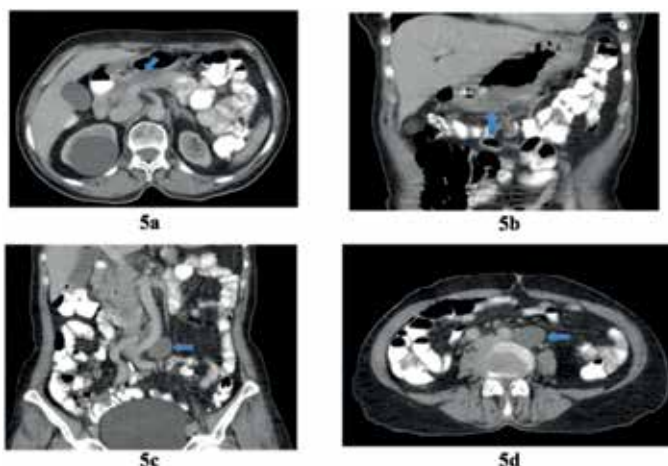


Figure 4. Computerized tomography-scan of the abdomen presented wall thickness of stomach and a solid mass near abdominal aorta

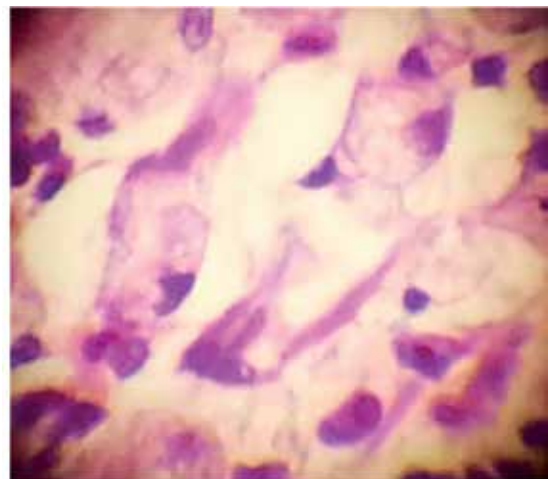


Figure 5. Gastric adenocarcinoma. Signet cells, including extracellular and intracellular mucin (10×40 H&E)

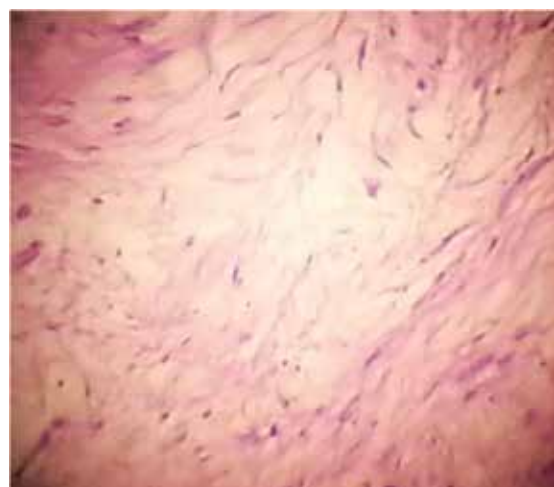


Figure 6. Schwannoma (10×20, H&E)

Following parathyroidectomy, serum calcium, phosphate and parathormone levels of the patient returned to normal. Her first-degree relatives were screened by laboratory tests. None of them showed any pathological laboratory abnormalities. Thus, further genetic investigation was not performed for the patient. After the recovery phase of the final surgery, the patient was referred to the medical oncology outpatient clinic in our hospital. Chemoradioterapy with adjuvant capecitabine was started. The patient is still being followed periodically by the medical oncology, general surgery and endocrinology departments.

Discussion

Intraabdominal schwannomas are very uncommon; benign schwannomas often do not produce any symptoms and they are diagnosed by chance as a coincidental finding. Gastrointestinal tract (GIT) schwannomas to be solid homogenous tumors, which are highly cellular and composed of spindle cells with positive staining for S100 protein (10,11). Since intraabdominal schwannomas are rare tumors, they are reported as an isolated case even when a solitary tumor is detected (9,10,11,12,13). Coexistence of these tumors with an additional tumor is even more unusual (14,15). For instance, some intraabdominal schwannomas may rarely coexist with another GIT tumor (16). In the literature, there are case reports of intraabdominal schwannomas occurring concurrently with GIT adenocarcinomas. A study performed in 1991 reported a MEN 1 coexisting with a peripheral nerve schwannoma which was considered a coincidental finding (17). Schwannomas may be seen in patients with NF but additional tumors and skin lesions that are observed in such patients were not present in our patient.

While a combination of gastric tumors and hypercalcemia is observed in MEN 1 (Wermer syndrome), the type of gastric tumor developing in this syndrome is usually a gastrinoma which belongs to the group of gastroenteropancreatic neuroendocrine tumors (1,3,11). However, although our patient had a parathyroid adenoma which can be a component of MEN syndromes, the coexisting gastric tumor was not a gastrinoma but a signet ring cell gastric adenocarcinoma. Other tumors that typically occur in MEN syndromes were absent in our patient except for parathyroid adenoma. Additionally, his serum calcitonin level was normal.

The coexistence of the aforementioned tumors in our patient was considered to occur sporadically since the tumors had a late onset and none of the first-degree relatives had similar neuroendocrine tumors. Thus, a more comprehensive screening for the extended family members was not conducted and serum calcium levels of her children were obtained only. His first-degree relatives were informed that such tumors may concurrently occur and were advised to consult an endocrinologist if they develop any of these tumors in the future to allow investigation of other potential coexisting tumors.

It is worth considering whether these three tumors that were concurrently diagnosed in our patient were associated with a clinical condition or represented a coincidental finding. For

example, there are some surface proteins which have been recently implicated in the development of tumors. The epithelial cell adhesion molecule, a transmembrane glycoprotein, has been reported to be associated with tumor development in various body parts (18,19). The expression of these surface proteins has been found to be associated with the development of parathyroid and gastric epithelial tumors. Additionally, hepatocyte paraffin 1, a monoclonal antibody, has been reported to be associated with lung adenocarcinoma, bladder, pancreatic, gastric, small intestine, colon, adrenal gland and some neuroendocrine tumors, such as paraganglioma and other tumors, including malignant melanoma (20). It seems plausible that the presence of multiple tumors that we observed in our patient may be explained by the expression of a surface protein.

Conclusion

Although the exact cause is unknown, the combination of intraabdominal schwannoma, parathyroid adenoma and gastric adenocarcinoma observed in our patient is the first case to be reported in the literature and represents a major clinical concern.

Ethics

Informed Consent was obtained from the patient.

Peer-review: Externally peer-reviewed.

Authorship Contributions

Surgical and Medical Practices: Ersin Ergün, Concept: Gülşah Elbüken, Design: Gülşah Elbüken, Data Collection or Processing: Özlem Öztürk, Literature Search: Selçuk Seber, Interpretation of Imaging: Mücahit Doğru, Ülkü Korkmaz, Writing: Gülşah Elbüken.

Conflict of Interest: No conflict of interest was declared by the authors.

Financial Disclosure: The authors declared that this case report has received no financial support.

References

1. Callender GG, Rich TA, Perrier ND. Multiple endocrine neoplasia syndromes. *Surg Clin North Am* 2008;88:863-895.
2. Huq A, Kentwell M, Tirimacco A, Rossini J, Rawlings L, Winship I. Vestibular schwannoma in a patient with neurofibromatosis type 1: clinical report and literature review. *Fam Cancer* 2015;14:157-160.
3. Wermer P. Endocrine adenomatosis and peptic ulcer in a large kindred. Inherited multiple tumors and mosaic pleiotropism in man. *Am J Med* 1963;35:205-212.
4. Warner JV, Nyholt DR, Busfield F, Epstein M, Burgess J, Stranks S, Hill P, Perry-Keene D, Learoyd D, Robinson B, Teh BT, Prins JB, Cardinal JW. Familial isolated hyperparathyroidism is linked to a 1.7 Mb region on chromosome 2p13.3-14. *J Med Genet* 2006;43:e12.
5. Schroeder RD, Angelo LS, Kurzrock R. NF2/merlin in hereditary neurofibromatosis 2 versus cancer: biologic mechanisms and clinical associations. *Oncotarget* 2014;5:67-77.
6. Thakker RV, Newey PJ, Walls GV, Bilezikian J, Dralle H, Ebeling PR, Melmed S, Sakurai A, Tonelli F, Brandi ML; Endocrine Society. Clinical practice guidelines for multiple endocrine neoplasia type 1 (MEN1). *J Clin Endocrinol Metab* 2012;97:2990-3011.

7. Taïeb D, Kebebew E, Castinetti F, Chen CC, Henry JF, Pacak K. Diagnosis and preoperative imaging of multiple endocrine neoplasia type 2: current status and future directions. *Clin Endocrinol (Oxf)* 2014;81:317-328.
8. Korf BR. Neurofibromatosis. *Handb Clin Neurol* 2013;111:333-340.
9. Hilton DA, Hanemann CO. Schwannomas and their pathogenesis. *Brain Pathol* 2014; 24:205-220.
10. Levy AD, Quiles AM, Miettinen M, Sobin LH. Gastrointestinal schwannomas: CT features with clinicopathologic correlation. *AJR Am J Roentgenol* 2005;184:797-802.
11. Khan AA, Schizas AM, Cresswell AB, Khan MK, Khawaja HT. Digestive tract schwannoma. *Dig Surg* 2006;23:265-269.
12. Kwon MS, Lee SS, Ahn GH. Schwannomas of the gastrointestinal tract: clinicopathological features of 12 cases including a case of esophageal tumor compared with those of gastrointestinal stromal tumors and leiomyomas of the gastrointestinal tract. *Pathol Res Pract* 2002;198:605-613.
13. Hou YY, Tan YS, Xu JF, Wang XN, Lu SH, Ji Y, Wang J, Zhu XZ. Schwannoma of the gastrointestinal tract: a clinicopathological, immunohistochemical and ultrastructural study of 33 cases. *Histopathology* 2006;48:536-545.
14. Manchanda C, Nagpal K, Cosgrove JM, Saraiya R. An unusual association of cerebral schwannoma, parathyroid adenoma, and papillary thyroid carcinoma. *Am Surg* 2012;78:375-376.
15. Hamby LS, Lee EY, Schwartz RW. Parathyroid adenoma and gastric carcinoma as manifestations of Cowden's disease. *Surgery* 1995;118:115-117.
16. Yang LH, Wang JO, Ma S, Zhu Z, Sun JX, Ding SL, Li G, Xu HT, Wang L, Dai SD, Liu Y, Miao Y, Jiang GY, Fan CF, Wang EH. Synchronous of gastric adenocarcinoma and schwannoma: report of a case and review of literatures. *Int J Clin Exp Pathol* 2015;8:1041-1045.
17. Shepherd JJ. The natural history of multiple endocrine neoplasia type 1. Highly uncommon or highly unrecognized? *Arch Surg* 1991;126:935-952.
18. Went P, Vasei M, Bubendorf L, Terracciano L, Tornillo L, Riede U, Kononen J, Simon R, Sauter G, Baeuerle PA. Frequent high-level expression of the immunotherapeutic target Ep-CAM in colon, stomach, prostate and lung cancers. *Br J Cancer* 2006;94:128-135.
19. van der Gun BT, Melchers LJ, Ruiters MH, de Leij LF, McLaughlin PM, Rots MG. EpCAM in carcinogenesis: the good, the bad or the ugly. *Carcinogenesis* 2010;31:1913-1921.
20. Lugli A, Tornillo L, Mirlacher M, Bundi M, Sauter G, Terracciano LM. Hepatocyte paraffin 1 expression in human normal and neoplastic tissues: tissue microarray analysis on 3,940 tissue samples. *Am J Clin Pathol* 2004;122:721-727.