



Papillary Thyroid Carcinoma in a Hemiagenetic Thyroid Gland: A Case Report

Hemiagenetik Tiroid Bezinde Gelişen Tiroid Papiller Kanseri: Olgu Sunumu

Oğuz Uğur Aydın, Alptekin Gürsoy*, Banu Bilezikçi**, Serdar Özbaş

Güven Hospital, Clinic of General Surgery, Ankara, Turkey

*Güven Hospital, Clinic of Endocrinology and Metabolism, Ankara, Turkey

**Güven Hospital, Clinic of Pathology, Ankara, Turkey

Abstract

Thyroid hemiagenesis is a rare congenital pathology and it is secondary to a defect which occurs during embryonic development of the thyroid tissue. Usually, diagnosis is incidentally made by imaging study of the neck or during diagnosis of a related thyroid gland disease. Absence of the left lobe is observed in near all cases, but involvement of the right lobe has also been reported in the literature, albeit very rare. Although true prevalence is not known, the reported prevalence ranges from 1/1900 to 1/2675. Presence of thyroid nodules, subacute thyroiditis, Hashimoto's thyroiditis and Grave's disease in thyroid hemiagenesis has previously been reported in the literature. Combination of thyroid papillary cancer and thyroid hemiagenesis is rarely reported. In this report, we present the case of papillary cancer in a solitary nodule in a hemiagenetic thyroid gland in a patient with Hashimoto's thyroiditis and treatment modalities thereof.

Keywords: Thyroid, papillary carcinoma, hemiagenesis

Öz

Tiroid hemiagenezisi nadir rastlanan konjenital bir patolojidir ve tiroid dokusunun embriyonik gelişimi sırasında oluşan defekte bağlı görülür. Tanı sıklıkla rastlantısal olarak boyuna ait bir görüntüleme veya ilişkili bir tiroid bezi hastalığının tanısı sırasında konmaktadır. Sol lobun yokluğu olguların neredeyse tamamında gözlenir ancak çok nadir olarak sağ lobun etkilendiği de literatürde tanımlanmıştır. Gerçek prevalansı bilinmemekle beraber görülme sıklığı 1/1900 ile 1/2675 arasında bildirilmiştir. Hemiagenetik tiroid bezinde, tiroid nodülleri, adenom, subakut tiroidit, Hashimoto tiroiditi ve Graves hastalığı daha önceden literatürde yer almıştır. Tiroid papiller kanser ve tiroid bezi hemiagenezisi birlikteliği ise çok daha nadir tanımlanmıştır. Bu olgu sunumunda, Hashimoto tiroiditi olan bir olgu da hemiagenetik tiroid bezinde gelişen tek nodülde saptanan papiller kanser ve tedavi modalitelerini sunduk.

Anahtar kelimeler: Tiroid, papiller karsinom, hemiagenesis

Introduction

Thyroid hemiagenesis is a rare congenital anomaly, which is characterized by agenesis of one thyroid lobe. Although many theories have been offered to explain developmental anomaly of one thyroid lobe, none of them can be evidenced to date. It has been reported that the prevalence of thyroid disease increases in those patients. Ultrasound and scintigraphy are diagnostic methods of choice. Papillary thyroid cancer is one of rare accompanying diseases in thyroid hemiagenesis. If central compartment lymph node dissection is carried out along with total thyroidectomy in surgical treatment of thyroid papillary cancer, where lymph node metastasis is commonly observed, recurrence decreases and disease-free survival prolongs.

Case Report

A 31-year-old male patient presented to the endocrinology clinic of our hospital with clinical picture of subclinical hypothyroidism

(thyroid - stimulating hormone: 10 mIU/L). Thyroid ultrasound demonstrated absence of the left lobe and isthmus of the thyroid gland (left hemiagenesis). Typical image of Hashimoto's thyroiditis was observed in the parenchyma of the right lobe and advanced stage heterogeneity, microcystic appearance and diffuse fibrous bands were found. A nodule, measuring 8x8x9 mm in size was observed at the inferior segment of the right lobe, and the hypoechoic nodule was characterized by irregular margins, compromised anterior/transverse diameter and suspicion of malignancy. Clinical examination was unremarkable. Ultrasound-guided fine needle aspiration biopsy (FNAB) was done in the light of those findings. Operation was planned after obtaining pathology report showing malignant cytology, favoring papillary cancer. Total thyroidectomy and prophylactic central compartment lymph node dissection were carried out for the patient whose preoperative thyroid functions were normal. On pathological examination of the specimen, macroscopic dimensions were measured 5.5x4x2.5 cm and a fat tissue with

internal central lymph nodes measuring 2.5x1.5x1 cm in size was found immediately inferior to the former one. An off-white solid tumor tissue, which was poor in colloid, and measuring 0.5 cm in size, was observed in heterogeneous parenchyma of the right lobe. Five lymph nodes were observed in the fat tissue which also included central lymph nodes. The following findings were reported on microscopic examination of the specimen: papillary thyroid carcinoma, Warthin type, 0.5 cm in diameter, tumor-free surgical margins, no lymphovascular invasion, well defined tumor, Hashimoto's thyroiditis in extra-tumoral tissue, hypoplastic left lobe, and five tumor-free lymph nodes at central compartment. No postoperative problem was experienced and the patient was discharged 24 hours later.

Discussion

Thyroid hemiagenesis is a rare thyroid pathology and it was first described by Handfield and Jones in early 1800s (1). It has been reported that the prevalence of thyroid disease increases in patients with thyroid hemiagenesis (2). It is also reported that extra thyroid pathologies, such as thyroiditis, carcinoma, adenoma, colloid nodule, subacute thyroiditis, Graves's disease and Hashimoto's thyroiditis, may develop in intact thyroid lobe (3,4,5). It is 3-fold more common in females (6). Since many patients do not manifest symptoms of thyroid disease, true prevalence is not known, but the reported prevalence ranges from 1/1900 to 1/2675 (2). Absence of the left thyroid lobe is observed in most patients, but agenesis of

isthmus is found in near half of patients (7). Our case manifested demographic and anatomic characteristics, which are consistent with the literature. Absence of one of the thyroid lobes on palpation is a diagnostic indicator of hemiagenesis. However, thyroid ultrasound and scintigraphy are diagnostic methods of choice. It is recommended to verify the diagnosis with ultrasound in order to rule out pathologies which lead to unilateral involvement as indicated by thyroid scintigraphy (unilateral subacute thyroiditis, post-inflammatory atrophy and suppression of the thyroid tissue by autonomous nodule) (5). Computed tomography and magnetic resonance imaging are other diagnostic methods. Our case was diagnosed with ultrasound and scintigraphy was not required (Figure 1A, 1B). FNAB specimen was taken from the nodule, approximately 7 to 8 mm in diameter, which was located in the right thyroid lobe and suspected for malignancy in the light of the ultrasound findings, and malignant cytology, suggestive of papillary cancer, was reported, and thus, total thyroidectomy and prophylactic central compartment lymph node dissection, pursuant to our clinical guideline, were carried out. When pre-thyroid strap muscles were separated from each other on mid-line, hemiagenetic thyroid gland was observed (Figure 2). Specimen had somewhat verified the diagnosis of hemiagenesis (Figure 3). Recently, prophylactic central lymph node dissection is more commonly performed in surgical management of papillary thyroid cancer. Lymph node metastasis is frequent in papillary thyroid cancer and micrometastasis is reported at a rate up to 90 percent (8,9). Central neck dissection may decrease loco-regional recurrence rates and postoperative serum triglyceride level especially in high-risk patient group; it may also prolong disease-free survival, but it is accompanied by increased risk of morbidity. Although prophylactic central compartment lymph node dissection (level 6) is recommended for patients with high-risk factors, there are some concerns for postoperative morbidity especially for low-risk patient group. Routine or prophylactic central compartment lymph node dissection is accompanied by very low morbidity rates in patients operated for papillary thyroid cancer in our clinic, and accordingly, we added prophylactic central compartment (level 6) dissection to total thyroidectomy. Thyroid hemiagenesis is a rare pathology and combination of thyroid hemiagenesis and papillary cancer is, of

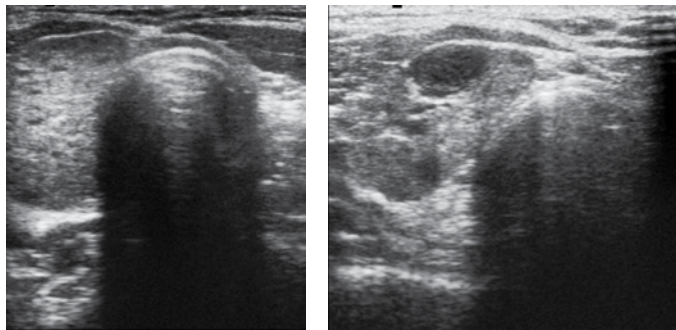


Figure 1. A and B. Ultrasonographic image of hemiagenetic thyroid gland

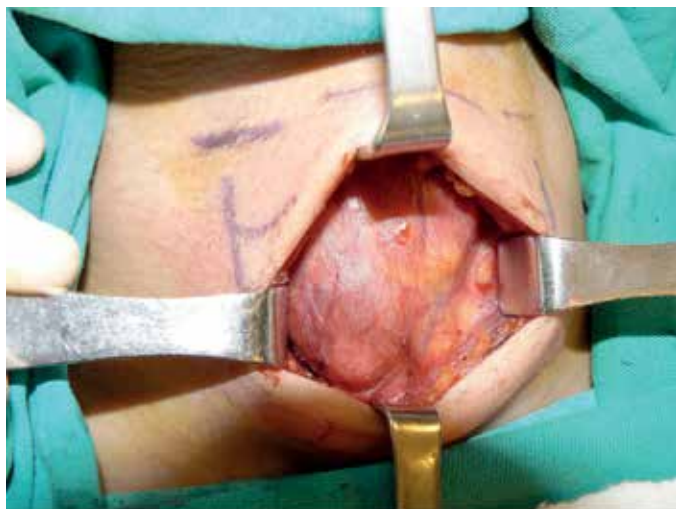


Figure 2. The image hemiagenetic thyroid gland in operation

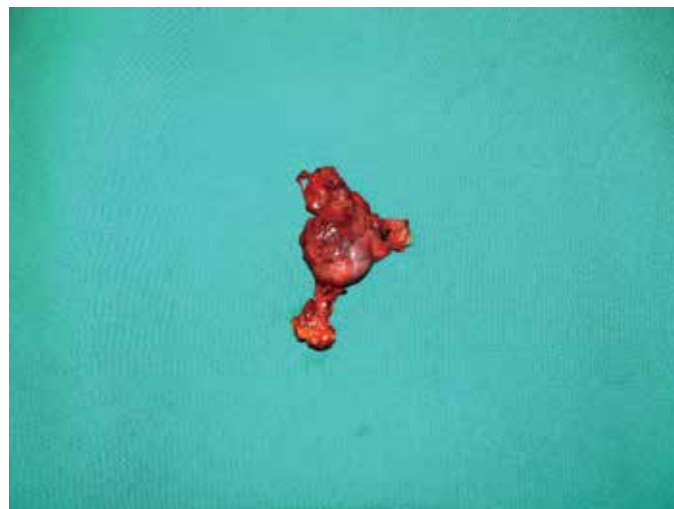

Figure 3. The image of specimen for hemiagenetic thyroid gland

course, a more rare entity. Total thyroidectomy is a frequently preferred approach. Therefore, hemiagenetic lobe should be intraoperatively explored and the surgeon should ensure that no residual thyroid tissue is left. Prophylactic central lymph node dissection is preferable approach, if it can be carried out with low morbidity risk.

Ethics

Peer-review: Externally peer-reviewed.

Authorship Contributions

Surgical and Medical Practices: Oğuz Uğur Aydın, Serdar Özbaş, Concept: Oğuz Uğur Aydın, Serdar Özbaş, Design: Alptekin Gürsoy, Serdar Özbaş, Data Collection or Processing: Oğuz Uğur Aydın, Banu Bilezikçi, Analysis or Interpretation: Serdar Özbaş, Alptekin Gürsoy, Literature Search: Banu Bilezikçi, Writing: Oğuz Uğur Aydın.

Conflict of Interest: No conflict of interest was declared by the authors. Financial Disclosure: The authors declared that this study received no financial support.

References

1. Handfield-Jones 1896 in: Henle J (ed) Handbuch der Systematischen Anatomie des Menschen. Friedrich Wlewig und Braunschweig, Sohn, p. 538.
2. Mikosh P, Gallowitsch HJ, Kresnik E, Molnar M, Gomez I, Lind P. Thyroid hemiagenesis in an endemic goiter area diagnosed by ultrasonography: report of sixteen patients. *Thyroid*. 1999;9:1075-1084.
3. Ozgen AG, Saygili F, Kabalak T. Thyroid hemiagenesis associated with Graves' disease and Graves' ophthalmopathy: Case Report. *Thyroid*. 2004;14:75-77.
4. Shibutani Y, Inoue D, Koshiyama H, Mori T. Thyroid hemiagenesis with subacute thyroiditis. *Thyroid*. 1995;5:133-135.
5. Karabay N, Çömlekçi, A, Canda MS, Bayraktar F, Degirmenci B. Thyroid hemiagenesis with multinodular goitre: a case report and review of the literature. *Endocr J*. 2003;50:409-413.
6. Pizzini AM, Papi G, Corrado S, Carani C, Roti E. Thyroid hemiagenesis and incidentally discovered papillary thyroid cancer: case report and review of the literature. *J Endocrinol Invest*. 2005;28:66-71.
7. Friedman A, Bauman A. Hemiagenesis of the thyroid. *South Med J*. 1979;72:927-929.
8. Şahin A, Koplay M, Seven B. Basit guatr ile birlikte olan tiroid hemiagenezi. *Tıp Araştırmaları Dergisi*. 2005;3:52-54.
9. Trimboli P, Ulisse S, Graziano FM, Marzullo A, Ruggieri M, Calvanese A, Piccirilli F, Cavaliere R, Fumarola A, D'Armiento M. Trend in thyroid carcinoma size, age at diagnosis and histology in a retrospective study of 500 cases diagnosed over 20 years. *Thyroid*. 2006;16:1151-1155.