



# A Case of Adrenal Mass Causing Adrenal Insufficiency: Tuberculosis

## Adrenal Yetmezliğe Neden Olan Adrenal Kitle: Tüberküloz

Pınar Şişman, Hande Peynirci, Özlem Saraydaroglu\*, Ahmet Bilgehan Şahin\*\*, Özen Öz Gül, Canan Ersoy

Uludağ University Faculty of Medicine, Department of Endocrinology and Metabolism, Bursa, Turkey

\*Uludağ University Faculty of Medicine, Department of Pathology, Bursa, Turkey

\*\*Uludağ University Faculty of Medicine, Department of Internal Medicine, Bursa, Turkey

### Abstract

Tuberculosis, the prevalence of which has continued to decline in developed countries, is still one of the reasons of adrenal insufficiency. In this report, we aimed to present a case of adrenal and miliary tuberculosis presenting with adrenal insufficiency. A 71-year-old woman with a history of unilateral adrenalectomy was admitted with the symptoms of adrenal insufficiency. In her further medical investigations, the diagnosis of primary adrenal insufficiency was established and a mass presenting as involvement of tuberculosis was detected in the adrenal gland. Bilateral pulmonary nodules compatible with miliary tuberculosis were observed. After anti-tuberculosis treatment, pulmonary nodules disappeared, but there was no significant decrease in the size of the adrenal mass. The patient, who underwent adrenalectomy, was followed with glucocorticoid and mineralocorticoid treatment. Tuberculosis of the adrenal glands is a common cause of adrenal insufficiency in developing countries. Tuberculosis can destroy the adrenal glands and the diagnosis of adrenal tuberculosis, especially presenting with enlargement of the adrenal glands, can be difficult.

**Keywords:** Adrenal mass, tuberculosis, adrenal insufficiency

### Öz

Tüberküloz, günümüzde, gelişmiş ülkelerde adrenal yetmezliğin sıklığı giderek azalan nedenlerinden biridir. Bu olgu sunumunda adrenal yetmezlik bulguları ile tanı alan adrenal ve miliyer akciğer tüberkülozlu hastayı sunmayı amaçladık. Yetmiş bir yaşında, daha önce tek taraflı adrenalectomi öyküsü olan kadın hasta adrenal yetmezlik semptomları ile başvurdu. Yapılan tetkiklerinde primer adrenal yetmezlik ve adrenal bezde tüberkülozun adrenal tutulumunu temsil eder nitelikte kitle saptandı. Her iki akciğerde miliyer tüberküloz ile uyumlu nodülleri mevcuttu. Anti-tüberküloz tedavi sonrası hastanın akciğerlerindeki nodüller kayboldu, adrenal kitle boyutlarında küçülme saptanmadı. Adrenalectomi yapılan hasta glukokortikoid ve mineralokortikoid tedavi ile takip edilmektedir. Adrenal tüberküloz gelişmekte olan ülkelerde halen adrenal yetmezliğin sık görülen nedenlerinden biridir. Tüberküloz adrenal bezde harabiyete neden olur ve özellikle adrenal bezde büyüme olan olgularda tanı güçtür.

**Anahtar kelimeler:** Adrenal kitle, tüberküloz, adrenal yetmezlik

### Introduction

Primary adrenal insufficiency (PAI) is an endocrine disease caused by bilateral adrenocortical destruction. It manifests as fatigue, loss of appetite, weight loss, nausea, vomiting, hypotension and hyperpigmentation. Clinical symptoms are observed when more than 80% of both adrenal glands are damaged. In the previous reports in the literature, tuberculosis was the main cause of adrenal insufficiency in 70-90% of cases, but, today, the leading cause of PAI is autoimmunity. However, in developing countries, tuberculosis still continues to be a common cause of PAI.

### Case Report

A 71-year-old female patient was admitted to the emergency department of our hospital with the complaints of fatigue, anorexia, nausea, weakness in the legs and inability to walk. Her complaints began in the last 2-3 months and intensified gradually. In her past medical history, 9 years ago she had the diagnosis of right infiltrative adrenal mass measuring 9x4x9 cm surrounding the inferior vena cava and extending to right retrocaval region which was thought to be non-adenoma in nature. When questioned in detail, it was learned that hormonal tests had been performed, the results had been considered to be nonfunctional, and she had undergone adrenal

biopsy. Pathological investigation showed malignant tumoral tissues. Therefore, right adrenalectomy and nephrectomy were performed. Light microscopic examination of the adrenalectomy specimen demonstrated epithelioid histiocytes, lymphocytes, plasmocytes, and granulomas consisting of Langhans-type multinucleate giant cells. Pathological examination report was consistent with granulomatous inflammation. In the pathological examination of the nephrectomy specimen and two lymph nodes, chronic pyelonephritis and granulomatous lymphadenitis were observed, respectively. Chest computed tomography (CT) scans were normal at that time. The patient did not attend follow-up visits after surgery, therefore, further investigations and assessments could not be performed.

On her admission to our emergency department, her axillary body temperature was 36.4 C, pulse rate-102 beats per minute, respiratory rate-24 breaths per minute and blood pressure was 80/60 mmHg. Her physical examination revealed mild hyperpigmentation on oral mucosa, palms and areolae. Laboratory tests showed elevated serum creatinine [1.7 mg/dL; normal range (NR): 0.6-1.3], hyponatremia (122 mmol/L; NR: 136-145) and hyperkalemia (7.8 mmol/dL; NR: 3.5-5.1). Electrocardiogram showed no evidence of hyperkalemia. Emergency dialysis was performed. Hypotension, hyperkalemia, and hyponatremia persisted after dialysis; therefore, the patient was investigated with a presumptive diagnosis of adrenal insufficiency. Adrenocorticotrophic hormone and basal cortisol levels were 291 pg/mL (NR: 5-46) and 1.9 µg/dL (NR: 3.7-19.4), respectively. She was diagnosed as having PAI, and methylprednisolone (60 mg/day) was started. The steroid dose was reduced gradually and treatment with prednisone 5 mg/day and fludrocortisone 0.1 mg/day was continued. With glucocorticoid and mineralocorticoid treatment, the complaints of weakness and loss of appetite regressed, serum sodium and potassium levels returned to normal.

On the abdominal CT images, an adrenal mass measuring 78x40 mm was detected in the left adrenal gland (Figure 1). Peripheral, but not central, enhancement was observed after contrast agent administration. It was considered to represent the adrenal gland involvement of tuberculosis. Chest CT scans revealed lots of millimeter-sized nodules in both lungs, more prominent in the upper lobes (Figure 2). It was consistent with miliary tuberculosis. On CT images, no pathologic lymph node was observed. Tuberculin skin test was negative. Bronchoscopy was performed. In both bronchial trees, the mucosa was edematous, fragile, and prone to bleeding, and anthracotic plaques were observed. Bronchoalveolar lavage showed dominant mononuclear cells (80%). It was negative Ziehl-Neelsen stain for acid fast bacilli. Cytological examination was benign and galactomannan test was negative. Serological tests for cytomegalovirus, Epstein-Barr virus, human immunodeficiency virus, *Salmonella*, and *Brucella* were all negative. Cultures for *Mycobacterium* and fungus were negative. Ophthalmic examination was normal. There was no sign of active tuberculosis infection in other body sites of the patient.

An anti-tuberculosis treatment including isoniazid (300 mg/day), rifampicin (600 mg/day), ethambutol (1500 mg/day) and pyrazinamide (2000 mg/day) was started. It lasted for one year. During follow-up visits, regression of the nodules was observed in consecutive posteroanterior chest X-rays. On chest CT scans after

treatment, nodules were totally disappeared (Figure 3). However, after treatment, the adrenal mass was similar in size and appearance on abdominal CT scans. Left adrenalectomy was performed. In the pathological examination of the specimen, there was a large necrotic area in the center, and mononuclear inflammatory cell infiltration, fibrosis and hyalinization in the peripheral regions of the mass (Figure 4). Besides, polymorphonuclear leukocytes were present around the mononuclear inflammatory cells. These findings were consistent with suppurative process on chronic granulomatous inflammation considering adrenal involvement of tuberculosis. After adrenalectomy the patient started replacement treatment and has been followed up with glucocorticoid and mineralocorticoid treatment since then.

## Discussion

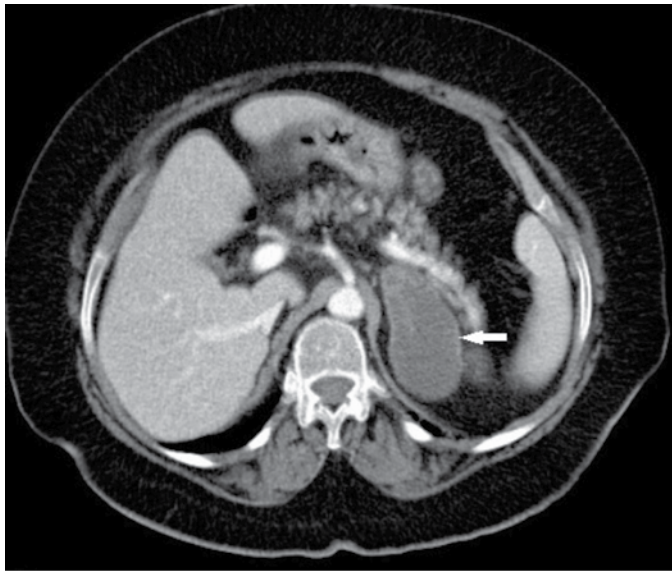
Tuberculosis is a disease caused by mycobacteria. Although its frequency decreased especially in developed countries worldwide, it is still a problem in underdeveloped regions of the world. Besides, nowadays, the increasing usage of immunosuppressant agents for different purposes leads to increased frequency of infections including tuberculosis. In immunocompromised patients, atypical organ involvements of tuberculosis are seen (1).

Adrenal tuberculosis is a result of hematogenous spread of systemic tuberculosis. Involvement of the adrenal gland is observed in 5-6% of cases with active disseminated tuberculosis (1,2,3). Adrenal insufficiency is a late finding of tuberculosis, and it is observed 10 to 15 years later after the onset of tuberculosis infection in the majority of cases (4). In adrenal tuberculosis, enlargement of adrenal gland and signs of extra-adrenal tuberculosis often exist (5). However, extra-adrenal tuberculosis can be clinically silent and active extra-adrenal tuberculosis cannot be diagnosed in approximately 12% of patients (2,3,6,7). In our case, at the time of detection of the first adrenal mass, there was no clinical manifestation of adrenal insufficiency because of the fact that contralateral adrenal gland was functioning. After surgery, the patient did not attend follow-up visits; therefore, further investigation for the detection of the primary focus of tuberculosis could not be performed. Due to the involvement of the remaining adrenal gland, the patient was admitted with the symptoms of acute adrenal insufficiency nine years after unilateral adrenalectomy.

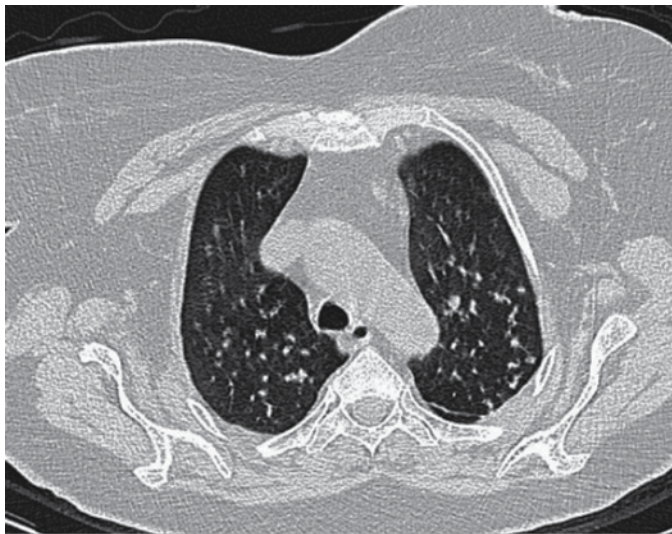
Abdominal CT has a high sensitivity and specificity for distinguishing tuberculosis from other tumors of the adrenal gland (7,8). However, it provides guidance in determining the etiology of PAI. The adrenal glands are usually atrophic in autoimmune disorders while enlargement of the adrenal glands may be observed in especially early stages of adrenal tuberculosis. Atrophy of the glands may be observed in late stages. CT provides information about beginning of the adrenal gland involvement and it is important in deciding which regimen to start. Calcification is a common finding in adrenal glands. However, enlargement of the adrenal glands can be seen without calcification in especially acute adrenal tuberculosis. Enlargement may be unilateral or bilateral (9).

In our patient, calcification was not detected on abdominal CT scans, but the staining pattern of the adrenal mass was consistent with the involvement of tuberculosis.

The effect of anti-tuberculosis treatment on improvement of adrenal function is controversial.



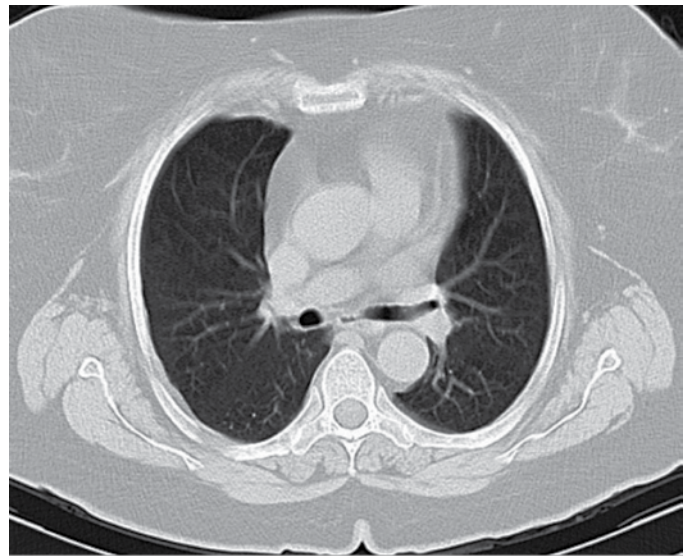
**Figure 1.** Adrenal mass, 78x40 mm in size, in left adrenal gland (white arrow) on abdominal computed tomography



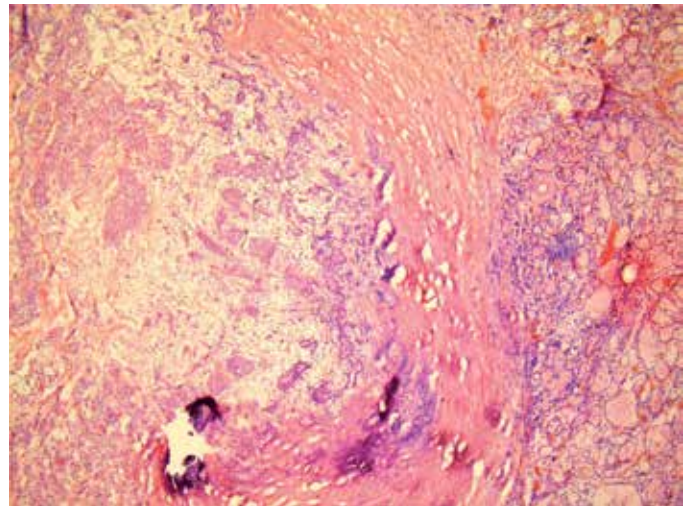
**Figure 2.** Widespread millimeter-sized nodules in both lungs, more prominent in the upper lobes on chest computed tomography

Although total functional improvement is rarely observed with anti-tuberculosis treatment, general consensus is that treatment cannot provide remission of the adrenal gland functions (4,8,9,10). Though nodules in the lungs disappeared with anti-tuberculosis treatment in our patient the adrenal mass did not get smaller. Therefore, adrenalectomy was performed.

In conclusion, adrenal tuberculosis may present with adrenal masses causing symptoms of adrenal insufficiency. Adrenal involvement of tuberculosis is one of the reasons for adrenal insufficiency. It is usually bilateral, but may also be unilateral. It should be kept in mind that adrenal insufficiency may not be observed in case of unilateral involvement. Extra-adrenal tuberculosis is usually clinically silent, thus, further investigations should be carried out to find the primary focus. In cases with extra-adrenal primary focus, signs and symptoms of adrenal insufficiency should be questioned and if suspicious, further investigations of the adrenal glands should be carried out. If early



**Figure 3.** The nodules were totally disappeared after treatment on chest computed tomography



**Figure 4.** In histopathological examination, polymorphonuclear leucocyte infiltration around necrotic area. Epithelioid histiocytes, lymphocytes, and Langhans-type multinucleated giant cells were seen

diagnosis of adrenal involvement is achieved and anti-tuberculosis treatment is started in the early stage of the disease, complete or partial remission of adrenal gland functions may be provided. However, early diagnosis and treatment cannot be achieved in majority of cases.

## Ethics

Informed Consent: Consent form was filled out by all participants.

Peer-review: Externally peer-reviewed.

## Authorship Contributions

Surgical and Medical Practices: Pinar Şişman, Canan Ersoy, Concept: Pinar Şişman, Canan Ersoy, Design: Pinar Şişman, Hande Peynirci, Data Collection or Processing: Pinar Şişman, Ahmet Bilgehan Şahin, Analysis or Interpretation: Pinar Şişman, Özlem Saraydaroglu,

Literature Search: Pınar Şişman, Özen Öz Gül, Writing: Pınar Şişman.  
Conflict of Interest: No conflict of interest was declared by the authors.  
Financial Disclosure: The authors declared that this study received no financial support.

## References

1. Ersoy C. Akciğer ve Akciğer Dışı Organ Tüberkülozları. In: Özyardımcı N, editor. Akciğer ve Akciğer Dışı Organ Tüberkülozları: Uludağ Üniversitesi Basımevi; 2008.p.215-219.
2. Aron DC FJ, Tyrrell JB. Glucocorticoids and adrenal androgens. In: Gardner DG SD, editor. Basic and Clinical Endocrinology. 1. 8 ed. USA: The McGraw-Hill Companies; 2007.p.346-395.
3. Hieronimus S, Bernard JL, Chevallier P, Chevallier A, Chyderiotis G, Fenichel P, Landraud L. Adrenal tuberculosis after a pheochromocytoma: a misleading tumoral presentation. Ann Endocrinol (Paris). 2007;68:191-195.
4. Alevritis EM, Sarubbi FA, Jordan RM, Peiris AN. Infectious causes of adrenal insufficiency. South Med J. 2003;96:888-890.
5. Vita JA, Silverberg SJ, Goland RS, Austin JH, Knowlton AI. Clinical clues to the cause of Addison's disease. Am J Med. 1985;78:461-466.
6. Kelestimur F, Unlu Y, Ozesmi M, Tolu I. A hormonal and radiological evaluation of adrenal gland in patients with acute or chronic pulmonary tuberculosis. Clin Endocrinol (Oxf). 1994;41:53-56.
7. Upadhyay J, Sudhindra P, Abraham G, Trivedi N. Tuberculosis of the adrenal gland: A case report and review of the literature of infections of the adrenal gland. Int J Endocrinol. 2014;2014:876037.
8. Sun ZH, Nomura K, Toraya S, Ujihara M, Horiba N, Suda T, Tsushima T, Demura H, Kono A. Clinical significance of adrenal computed tomography in Addison's disease. Endocrinol Jpn. 1992;39:563-569.
9. Bhatia E, Jain SK, Gupta RK, Pandey R. Tuberculous Addison's disease: Lack of normalization of adrenocortical function after anti-tuberculous chemotherapy. Clin Endocrinol (Oxf). 1998;48:355-359.
10. Penrice J, Nussey SS. Recovery of adrenal function following treatment of tuberculous Addison's disease. Postgrad Med J. 1992;68:204-205.