



# 5-Alpha Reductase Deficiency: A Review of Five Cases Diagnosed with Ambiguous Genitalia

## 5-Alfa Redüktaz Eksikliği: Ambigus Genitalya Tanılı Beş Vaka

Zafer Pekkolay, Faruk Kılınç, Şadiye Altun Tuzcu\*, Hikmet Soylu, Alpaslan Kemal Tuzcu

Dicle University Faculty of Medicine, Division of Endocrinology and Metabolism, Diyarbakır, Turkey  
\* Diyarbakır Gazi Yaşargil Training and Research Hospital, Clinic of Nuclear Medicine, Diyarbakır, Turkey

### Abstract

5-alpha reductase is an enzyme which is responsible for the conversion of testosterone to dihydrotestosterone (DHT) in the peripheral tissues. It plays a key role in the development of male external genitalia. The present study was carried to make a clinical presentation of five male patients diagnosed with 5-alpha reductase deficiency resulting in the developmental disorder of male sexuality as well as to draw attention to the patients' medical history, physical examination and laboratory features.

A test group comprising of five male subjects previously diagnosed with 5-alpha reductase deficiency after being hospitalized and a series of examinations between April 2007 and July 2014, were enrolled in the study. Physical examination, hormonal profiles, radiological findings and karyotype analyses of the patients were carried out and their previous medical history was recorded.

All the patients with karyotype 46 XY were raised as a female. They had external genitalia similar to each other and expressed a lower level of DHT.

The patients with a disorder of male sex development, who expressed lower levels of dihydrotestosterone, must be checked for 5-alpha reductase deficiency.

**Keywords:** 5-alpha reductase deficiency, dihydrotestosterone, ambiguous genitalia

### Özet

Dihidrotestosteron (DHT) periferik dokularda testosterondan 5-alfa redüktaz enzimiyle oluşmaktadır. Erkek dış genitalyasının gelişiminde anahtar role sahiptir. Bu çalışmanın amacı, cinsel gelişim bozukluğu nedeniyle kliniğimize yatırılan 5-alfa redüktaz eksikliği tanısı konulmuş olan 5 erkek hastanın klinik durumlarını paylaşmak ve nadir görülen bu hastalığın anamnez, fizik muayene, laboratuvar özelliklerine dikkat çekmektir.

Nisan 2007-Temmuz 2014 tarihleri arasında erkek cinsel gelişim bozukluğu ön tanısıyla yatırılan ve yapılan değerlendirilmeler sonrasında 5-alfa redüktaz eksikliği tanısı konulmuş 5 erkek vaka çalışmaya alınmıştır. Hastaların geçmiş dosyalarından öyküleri, fizik muayene özellikleri, hormon profilleri, radyolojik görüntüleri ve karyotip analiz raporlarına bakıldı.

Hastaların hepsi kız çocuk olarak yetiştirilmişti. Tüm hastaların karyotipi 46 XY idi. Dış genital yapıları benzerdi. Bütün hastaların DHT düzeyleri düşüktü.

Erkek cinsel gelişim bozukluğu olan hastalarda dihidrotestosteron düşük bulunursa 5-alfa redüktaz eksikliği düşünülmelidir.

**Anahtar kelimeler:** 5-alfa redüktaz eksikliği, dihidrotestosteron, ambigus genitalya

### Introduction

In peripheral tissues, 5-alpha reductase enzyme converts testosterone into dihydrotestosterone (DHT). DHT is a more potent hor-

mone as compared to testosterone. It is the main hormone which induces the process of masculinity in the male fetus, in the maternal womb and enables the development of external genitalia. In cases of the deficiency of 5-alpha reductase enzyme, this conver-

sion does not take place resulting in ambiguous genitalia in the male fetus. Scrotum, micropenis, and pseudovagina that have not completed their fusion are apparent as labia, clitoris, and normal vagina, respectively (1). A disorder of sex development, 5-alpha reductase deficiency, is a rare autosomal recessively transmitted condition with 46 XY karyotype. It was first defined in a patient with hypospadias, pseudovagina, micropallus, and undescended testicles in 1974 (2). Testosterone allows the differentiation of Wolffian duct, contributing to the formation of vasa deferentia, epididymis, and seminal vesicles. The internal genital organs of patients included in the study were found to be normal. As a result of decreased DHT, the adult patients presented decreased male-type body hair development as well as a sparse beard. Since the enlargement of the prostate is associated with the level of DHT, such patients presented smaller prostates (3). Though these patients have been raised as females; yet, their secondary sexual characters during puberty were towards masculinity under the effect of testosterone hormones, which led to serious psycho-social problems both, in the patient as well as in their parents. 5-alpha reductase has two isoenzymes, one of which is known as "type-1", which is specific to brain, ovary and the entire skin except for genitalia. Type 2 isoenzyme is only found in the epididymis, seminal vesicles, genital skin, uterus, breast, hair follicle and the placenta. Both type 1 and type 2 isoenzymes exist in the liver, prostate, and testicles. Usually, patients present with a deficiency of type 2 enzyme (4). Numerous genetic mutations involving 5-alpha reductase type 2 enzyme were identified, most of which belonged to the patients with consanguinity.

## Material and Method

A group of five male patients who were hospitalized with a pre-diagnosis of disorder of male sexual development and diagnosed with 5-alpha reductase deficiency after assessment between April 2007 and July 2014, were included in the present study after retrospective examination. Patient data were obtained from the hospital records as well as from the file system of the endocrinology clinic and were recorded. Assessment criteria included anamnesis of features of physical examination, laboratory results, karyotype analyses, pelvic monitoring (MRI, USG) and psychiatric history.

## Findings

All the patients were males ranging in age between 19 and 24 years, having a mean age of  $21.4 \pm 2.5$  (Table 1). However, each of

them, having a karyotype of 46 XY, was raised as a female. In all patients, male body structures, enlargement of testis, micropenis or phallus were observed during puberty. In addition, all the patients had hypospadias and blind vaginal pouch. The tendency towards masculinity became more apparent after the end of puberty. All the patients were enrolled to the outpatient clinic for undergoing transsexual surgeries. The DHT levels in these patients were remarkably low. Out of five, three patients belonged to the same family, while the remaining two belonged to another family. Yet, there was first degree of consanguinity in the individuals between these groups, no gynecomastia was found in any of the patients. Ovary or uterus was not found in any of the patients at the time of monitoring. The testicles were mostly within the inguinal channel, except in one patient where testicles were found within the scrotum. All the patients were assessed by a board of psychiatrists. Consequently, all were approved for transsexual surgery after one-year follow-up.

## Case Reports

**Case 1:** A 19-year-old patient dressed in women's clothing reported to our outpatient clinic for the disorder of sexual development. During the physical examination, male body structure and external genitalia showed ambiguous genitalia. A testicle was present both, at the right inguinal channel and left the inguinal channel, 22x15 mm and 23x16 mm in size, respectively.

**Case 2:** A 22-year-old patient with feminine appearance reported for transsexual surgery. He had ambiguous genitalia and testicles measuring 27x24x32 mm at the right and 23x28x43 mm at the left side (Figure 1).

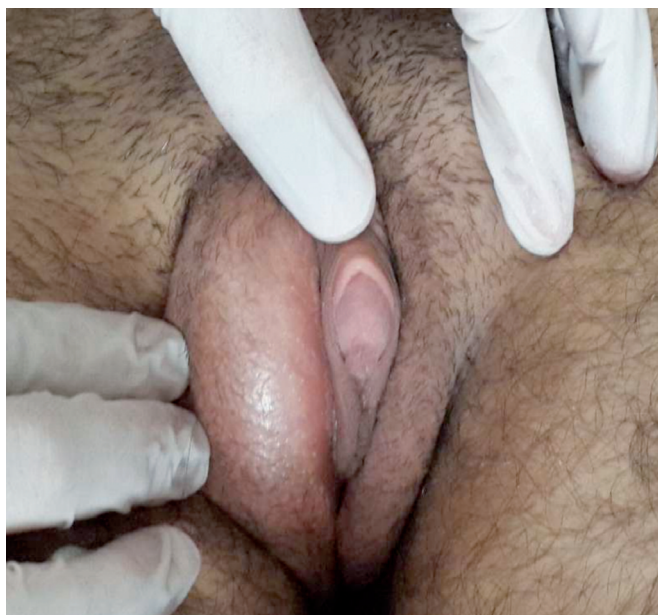**Case 3:** A 24-year-old patient with feminine appearance reported to our outpatient clinic for transsexual surgery. He had been raised as a female. During puberty, his sex development was towards masculinity. Physical examination revealed micropenis, hypospadias, testicles at labia and pseudovagina (Figure 2). Testicles measuring 27x30 mm at the left side and 19x24 mm at the right side were found at both inguinal channels.

**Case 4:** A 20-year-old patient with feminine appearance reported to our outpatient clinic for transsexual surgery. He had ambiguous genitalia. Testicles measuring 21x18 mm at the left side and 25x16 mm at the right side, were also present at both inguinal channels.

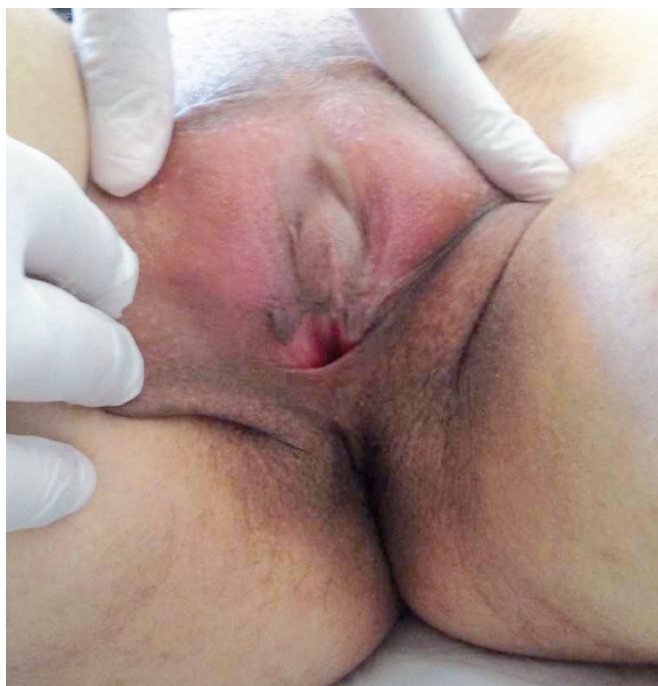
**Case 5:** A 22-year-old patient with feminine appearance reported to our outpatient clinic for transsexual surgery. Testicles measur-

Table 1. Laboratory and clinical features of the patients.

Cases	DHT (250-990 pg/ml)	Testosterone (2.18-9.05 ng/ml)	T / DHT (3-4)	Bilateral Testicles	Identity/Name/ Karyotype	Uterus/ Ovary	Hypospadias/ Vaginal pouch
Case 1	49.4 ↓	5.38	108.90 ↑	Yes-inguinal	Female/Female/ 46XY	No / No	Yes / Yes
Case 2	73 ↓	10.65	145.89 ↑	Yes -scrotum	Female/Female/ 46XY	No / No	Yes / Yes
Case 3	22.2 ↓	6.44	290.09 ↑	Yes -inguinal	Female/Female/ 46XY	No / No	Yes / Yes
Case 4	130 ↓	9.99	76.84 ↑	Yes -inguinal	Female/Female/ 46XY	No / No	Yes / Yes
Case 5	160 ↓	8.45	52.81 ↑	Yes -inguinal	Female/Female/ 46XY	No / No	Yes / Yes



**Figure 1:** Micropenis-testicles-in-labias.



**Figure 2:** Phallus-blind-vaginal-pouch.

ing 37x24 mm at the left side and 38x21 mm at the right side, were present at both inguinal channels.

## Discussion

Testosterone is converted into dihydrotestosterone by the 5-alpha reductase enzyme. DHT, mainly responsible for the development of male external genitalia, enables the enlargement of the phallus,

the fusion of labia and growth of the scrotum. These patients were born with an ambiguous genitalia. Afterward, the scrotum appears like labia and the penis like clitoromegaly. Besides this, at various levels, the hypospadias-blind vaginal pouch can also be seen and testicles may remain either in the inguinal channel or within the labia, rarely being in scrotum as well (5). All of the patients had been raised as females due to ambiguous genitalia at the time of birth. 5-alpha reductase deficiency presents with an autosomal recessive transmission pattern. Individuals with this syndrome have normal internal genital organs. Male-type muscle patterns, hair development, voice deepening and spermatogenesis occur during puberty (6). Among the five patients, three patients belonged to the same family, while the remaining two belonged to another family. A first-degree kinship was seen amongst the individuals between these groups. The karyotype in the patients was 46 XY. Due to ambiguous genitalia during delivery, all these patients were raised as females. During puberty, sexual development was towards masculinity. Afterward, these patients underwent transsexual surgeries from femininity to masculinity (7). The common feature of all of these patients is that they have micropenis (8). All patients in the present study also had a micropenis. In some occasions, patients may be thought to be affected by an inguinal hernia during childhood and, in turn, their testes may be surgically removed (9). It is therefore very important for this disorder to be detected during childhood and it must be followed up with a multidisciplinary approach, also involving the parents. Some require surgical intervention and psychotherapy involving the parents. Dihydrotestosterone, the hormone that is usually deficient, may be administered percutaneously (10). Surgical procedures include surgeries of micropenis, hypospadias, undescended testicle, and bifid scrotum (11). Lower levels of DHT in patients with 5-alpha reductase deficiency results in a more viscous as well as decreased volume of semen during ejaculation. Undescended testicles and surgical complications reduce the quality of spermatogenesis, which in turn decreases the likelihood of fertility. Azoospermia and Oligospermia may occur. Yet, early repair of undescended testicles and hypospadias may decrease the risk of such a complication. In patients with a certain level of mutation, spontaneous fertility is sometimes also seen. In some patients, an assisted reproductive technique also successfully incorporates fertility (12, 13). Testosterone levels in these patients were normal though the DHT levels are low.

## Conclusion

In the patients with a male disorder of sex development, having low levels of dihydrotestosterone, 5-alpha reductase deficiency should also be considered. The diagnosis, treatment, and follow-up of 5-alpha reductase deficiency involve a multidisciplinary approach.

## Ethics

The study has been approved by an institutional Ethics Committee of Dicle University Faculty of Medicine (308/30.07.2015). Informed Consent: Informed consent was obtained from the patients.

### Authorship Contributions

Concept: Alpaslan Kemal Tuzcu, Design: Faruk Kılınc, Data Collection or Processing: Zafer Pekkolay, Analysis or Interpretation: Hikmet Soylu, Literature Search: Zafer Pekkolay, Writing: Şadiye Altun Tuzcu.

Conflict of Interest: No conflict of interest was declared by the authors.

Financial Disclosure: The authors declared that this study received no financial support.

### References

1. Okeigwe I, Kuohung W. 5-Alpha reductase deficiency: a 40-year retrospective review. *Curr Opin Endocrinol Diabetes Obes.* 2014;21:483-487.
2. Imperato-McGinley J, Guerrero L, Gautier T, Peterson RE. Steroid 5alpha-reductase deficiency in man: an inherited form of male pseudohermaphroditism. *Science.* 1974;186:1213-1215.
3. Imperato-McGinley J, Zhu YS. Androgens and male physiology the syndrome of 5alpha-reductase-2 deficiency. *Mol Cell Endocrinol.* 2002;198:51-59.
4. Di Marco C, Bulotta AL, Varetti C, Dosa L, Michelucci A, Baldinotti F, Meucci D, Castagnini C, Lo Rizzo C, Di Maggio G, Simi P, Mari F, Berteloni S, Renieri A, Messina M. Ambiguous external genitalia due to defect of 5-alpha-reductase in seven Iraqi patients: prevalence of a novel mutation. *Gene.* 2013;526:490-493.
5. Sultan C, Lumbroso S, Paris F, Jeandel C, Terouanne B, Belon C, Audran F, Poujol N, Georget V, Gobinet J, Jalaguier S, Auzou G, Nicolas JC. Disorders of androgen action. *Semin Reprod Med.* 2002;20:217-228.
6. Randall VA. Role of 5 alpha-reductase in health and disease. *Baillieres Clin Endocrinol Metab.* 1994;8:405-431.
7. Price P, Wass JA, Griffin JE, Leshin M, Savage MO, Large DM, Bu'Lock DE, Anderson DC, Wilson JD, Besser GM. High dose androgen therapy in male pseudohermaphroditism due to 5 alpha-reductase deficiency and disorders of the androgen receptor. *J Clin Invest.* 1984;74:1496-1508.
8. Ng WK, Taylor NF, Hughes IA, Taylor J, Ransley PG, Grant DB. 5 alpha-reductase deficiency without hypospadias. *Arch Dis Child.* 1990;65:1166-1167.
9. Punnose J, Mathew KS, Ahmed HF. 5-Alpha-reductase deficiency in a Saudi "girl". *Postgrad Med J.* 1995;71:701.
10. Cheon CK. Practical approach to steroid 5alpha-reductase type 2 deficiency. *Eur J Pediatr.* 2011;170:1-8.
11. Vidal I, Gorduza DB, Haraux E, Gay CL, Chatelain P, Nicolino M, Mure PY, Mouriquand P. Surgical options in disorders of sex development (dsd) with ambiguous genitalia. *Best Pract Res Clin Endocrinol Metab.* 2010;24:311-324.
12. Marumudi E, Ammini AC. Fertility in patients with 5-alpha-reductase-2 deficiency. *Fertil Steril.* 2011;95:e.45.
13. Nordenskjöld A, Ivarsson SA. Molecular characterization of 5 alpha-reductase type 2 deficiency and fertility in a Swedish family. *J Clin Endocrinol Metab.* 1998;83:3236-3238.