



Asthmatic with Oral Steroid Usage Presenting with Multiple Fragility Fractures of Spine and Resultant Paraplegia: A Case Report

Oral Steroid Kullanan ve Omurgasında Paraplejiyle Sonuçlanan Multipl Frajilite Kırıkları ile Prezente Olan Astım Hastası: Olgu Sunumu

Syed Hunain Riaz, Ali Jawa*

Allama Iqbal Medical College, Department of Endocrinology, Lahore, Pakistan

*Shaheed Zulfiqar Ali Bhutto Medical University, Department of Endocrinology, PIMS, Islamabad, Pakistan

Abstract

Glucocorticoid induced osteoporosis can cause vertebral fractures. However, neurological complications such as spinal cord compression are rare. Here, we report a case study of a 55-year-old asthmatic male patient, who was on high doses of oral as well as inhaled steroids for uncontrolled bronchial asthma, was presented to the emergency room with paraplegia and urinary incontinence for a week. He showed the clinical features of cord compression with a sensory level at T10. His workup revealed a fracture of vertebrae T6, T8, T12 and L2 with cord contusion and edema at multiple levels on MRI. Osteomalacia was present as well and DXA scan revealed the lowest individual T-score of -3.4 at the lumbar spine. Surgical intervention was deferred due to fragile nature of the fractured spine and patient was treated with teriparatide (recombinant PTH), oral steroid dose was gradually reduced, and supportive care was given.

Keywords: Osteoporosis; oral glucocorticoids; vertebral fractures; spinal cord compression; paraplegia

Özet

Osteoporoz, vertebra kırıklarına neden olabilen bir durumdur. Ancak, spinal kord basısı gibi nörolojik komplikasyonlar nadirdir. Bu çalışmada, kontrol edilemeyen bronşiyal astım nedeni ile ağızdan yüksek doz inhale steroid kullanan 55 yaşındaki bir erkek hastanın, parapleji ve bir haftalık idrar inkontinansı şikâyeti ile acil servis başvurusu rapor edilmiştir. Hasta, T10 duyu düzeyinde kord basısına benzer klinik özellikler taşımakta idi. Manyetik rezonans görüntüleme sonucunda; T6, T8, T12 ve L2 vertebra kırıkları ile kord kontüzyonu ve çok seviyede ödem izlenmiştir. Hastada aynı zamanda osteomalazi saptanmıştır. *Dual X-ray absorptiyometri* taramasında lumbar omurgada en düşük T-skoru -3,4 elde edilmiştir. Cerrahi girişim kırık omurganın frajil durumu nedeni ile tercih edilmemiş, hasta teriparatid (rekombinant *paratiroid hormon*) tedavi edilmiş, ağızdan aldığı steroid dozlar yavaşça azaltılmış ve destek tedavisi verilmiştir.

Anahtar kelimeler: Osteoporoz; oral glukokortikoidler; vertebra kırıkları; spinal kord kompresyonu; parapleji

Introduction

Glucocorticoids are used by about 0.9% of the total population worldwide and up to 2.5% constitute the age group of 70-79. In the United States, glucocorticoids are prescribed to about 1 million patients annually (1). The secondary osteoporosis is one of the most common medical problems associated with the chronic use of glucocorticoids, and vertebral fractures are a devastating complication affecting 30-50% of patients (2, 3). Neurological complications are a rare incident in osteoporotic vertebral fractures (4). A lower bone

mineral density (BMD) shown in the patients with bronchial asthma may be due to the chronic use of inhaled steroids along with intermediate doses of oral steroids either separately or in combinations (5, 6). Several factors such as age, BMI, fall risk, gonadal status, physical activity, and calcium as well as vitamin D levels are taken into account while assessing a patient with glucocorticoid induced osteoporosis (7). We report a case with multiple osteoporotic compression fractures of the vertebral column and resultant paraplegia.

Address for Correspondence: Syed Hunain Riaz, Allama Iqbal Medical College, Department of Medicine, Lahore, Pakistan

Phone: +92-333-4262531 E-mail: syedhunain@gmail.com **Received:** 22/09/2015 **Accepted:** 24/10/2016

Case Report

A 55-years-old non-smoker Pakistani male patient was presented to the emergency room (ER) with one-week history of weakness in legs and urinary incontinence. The weakness was preceded by sudden severe back pain and followed by paresthesia. There was no history of minor or major trauma. He was a pre-diagnosed asthmatic and was on inhaled -2 agonists/steroids (salbutamol/beclomethasone) and oral prednisolone (up to 20 mg/day) intermittently for the past 2-3 years for uncontrolled asthma. He was not given calcium/vitamin D supplements. He had a cushingoid appearance (moon face, buffalo hump and wasting of limb muscles), was paraplegic with 1/5 power in both lower limbs, flaccid weakness, absent ankle, knee jerks and a positive Babinski reflex. The sensory level was at T10. Since there was urinary incontinence, the patient was catheterized.

Urine was negative for Bence-Jones proteins. The whole body examination for any malignancy which could have seeded to the spine was normal. The T2 weighted MRI of the spine (Figure 1) revealed totally collapsed T8 vertebra, and partial collapse at T6, T12, and L2 vertebrae. The height of T4 vertebra was also reduced. The osseous fragments of T8 and T12 were pushing backward into the spinal canal causing narrowing and spine cord contusion and edema. A DEXA scan showed a lowest individual T-score of -3.4 at the lumbar spine (Figure 2). Vitamin D levels were low (17 ng/dL) along with corrected serum calcium of 8.3 mg/dL (8.5-10.5) and serum phosphorus of 3.4 mg/dL (2.5-4.5). Alkaline phosphatase was 290 IU (NL up to 306). Due to the fragile nature of spine, surgical intervention was deferred and the patient was managed conservatively with supportive care, gradual reduction of oral steroids, high dose vitamin D and calcium supplementation and Teriparatide (recombinant PTH) to mitigate further fracture risk.

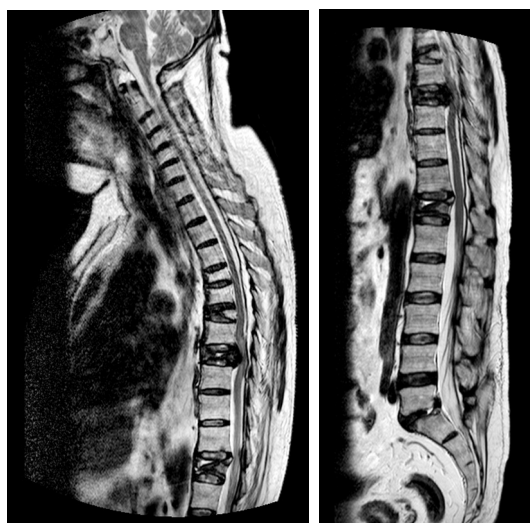


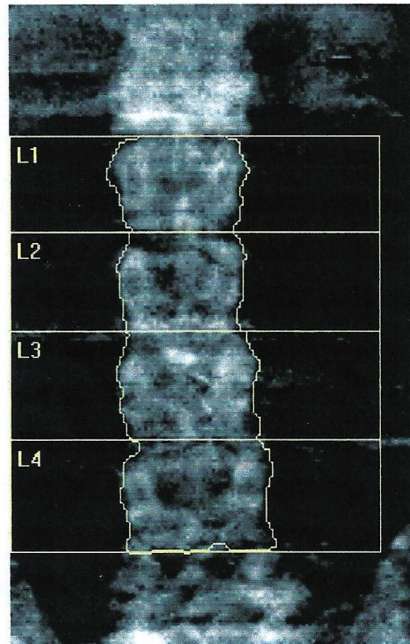
Figure 1a and b: T2W MRI of spine; the sagittal view showing totally collapsed T8 and partially collapsed T6, T12, and L2. The height of T4 is also reduced. There is a contusion of the spinal cord at levels of T8 and T12 due to osseous fragments of collapsed vertebrae.

Discussion

In a study, Angeli et al. showed that more than 37% of chronic glucocorticoid-treated patients had asymptomatic vertebral fractures, while more than 14% had two or more (2). The incidence of neurological complications of osteoporotic vertebral fractures is very rare but should be ruled out (4). Lee and Yip (1996) followed up 497 patients of 65-94 years with vertebral fractures and found that only 2% of them had spinal cord compression (4). Glucocorticoids affect the bone cells as well as a bone turnover by stimulating osteoclastic activity (bone resorption) and inhibiting osteoblastic activity (bone formation) (8). Besides, they also cause secondary hyperparathyroidism and reduce the synthesis of adrenal androgens, testosterone, and estrogen, which eventually lead to accelerated bone resorption (9, 10). The risk of fractures proportionately increases with daily doses and duration of treatment (3-6 months) (11). It has been shown that the risk of fracture increases even with glucocorticoid doses between 2.5 and 7.5 mg/day; however, the doses and treatment duration collectively are important predictors of fracture risk (12). Among the numerous medical applications of glucocorticoids, bronchial asthma is one, where they are used in inhaled as well as oral forms. Bronchial asthma itself predisposes the patients to osteoporosis (13). The local application of steroids (inhaled, topical) do not increase the risk of fracture unless the daily dose of prednisolone is > 7.5 mg (875 µg of budesonide or beclomethasone) (14). There have been published several reports and series on senile osteoporosis with spinal cord compression following minor or major trauma. Taggard and Tweedie (1987) reported two cases of spinal compression, along with senile osteoporosis (ages > 75 years) (15). Salmon and Choprin (1988) reported a 65-year-old white woman with spinal compression following osteoporotic fractures of thoracolumbar spine (16). Demir et al. (2007) reported a 73-year-old woman with a compression fracture at T7-T8 and resultant spinal compression (17). To the best of our knowledge, the only case in the literature pertaining to glucocorticoid induced osteoporotic vertebral fractures and spinal compression was reported by O'Conner & Phillip (2002) (18). An 88-year-old lady, who was on oral steroids for 40 years, suffered a spontaneous fracture of T5 and gradual neurological impairment due to cord compression. In our report, a 55-year-old male is much younger than the cases of complicated osteoporotic vertebral fractures report so far. The cases reported earlier have either single or adjacent vertebral fractures (19); however, the present case shows multiple non-adjacent fractures. According to the literature, neurological complications with vertebral compression fractures occur with less incidence, with gradual onset (20) and spontaneous recovery can occur (18). However, in our case, neurological impairment was developed only a week after the ominous back pain, which shows the rapidly progressive nature of the neurological damage. Such a severity of osteoporosis can be attributed to the cumulative effect of dose and duration of the inhaled as well as oral steroids as mentioned earlier in the literature (11, 12). The low vitamin D levels can also be contributive as vitamin D deficiency is reported to be as high as 92% in human population (21) and moreover, the supplementation of Vitamin D and calcium above the maintenance dose (800-1200 IU/day) (22)

Name: [REDACTED]	Sex: Male	[REDACTED]
Patient ID: 14212-11	Ethnicity: Asian	[REDACTED]
DOB: 01 January 1956		Age: 55

Referring Physician: MAYO HOSPITAL LAHORE.



k = 1.131, d0 = 45.3
116 x 131

Scan Information:

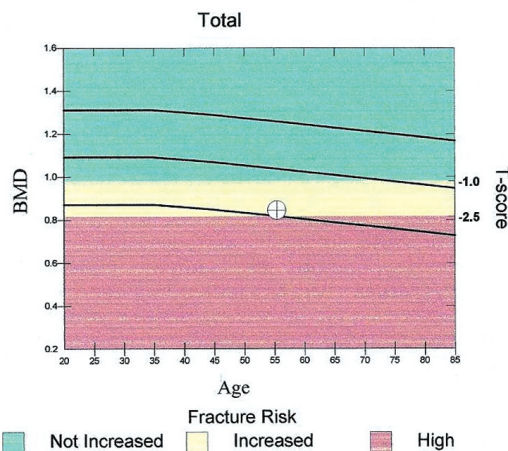
Scan Date: 30 May 2011 ID: A0530110D
Scan Type: x Lumbar Spine
Model: Discovery W (S/N 82330)
Comment:

DXA Results Summary:

Region	Area (cm ²)	BMC (g)	BMD (g/cm ²)	T - score	Z - score
L1	11.70	10.81	0.924	-0.8	-0.3
L2	11.66	9.41	0.807	-2.6	-2.1
L3	14.23	12.65	0.889	-1.9	-1.4
L4	15.72	12.16	0.773	-3.4	-2.9
Total	53.31	45.03	0.845	-2.2	-1.7

Total BMD CV 1.0%, ACF = 1.027, BCF = 1.005, TH = 8.000

WHO Classification: Osteopenia
Fracture Risk: Increased



Physician's Comment:

SLIGHTLY REDUCED BONE MINERAL DENSITY.

Figure 2: DEXA scan, showing a total T-score of -2.2 (osteopenia) at the lumbar spine and lowest individual T-score of -3.4. T-score vs. White Male; Z-score vs. White Male. Source: Hologic.

cannot be enhanced for the prevention of glucocorticoid induced osteoporosis (5, 6). Factors such as age, BMI, fall risk, gonadal status, and physical activity are taken into consideration during the assessment of a patient with glucocorticoid induced osteoporosis (23). To the best of our knowledge, this is the first case of its kind in the literature, which shows the devastating nature of steroid induced osteoporosis that can eventually lead to permanent disability and dependency.

Conclusion

Glucocorticoid induced osteoporosis can cause crippling neurological complications along with vertebral fractures and spinal cord compression. Glucocorticoids, especially in oral forms should be used judiciously and that too in a minimum effective dose and for the shortest durations. It is vital to assess for fracture risk before initiating glucocorticoids and regular follow ups with clinical assessment and BMD. Vitamin D and calcium supplementation

should be mandatory especially in populations where the prevalence of vitamin D deficiency is high along with bisphosphonate therapy where indicated.

Author Contributions

Concept: Syed Hunain Riaz, Design: Syed Hunain Riaz, Data Collection or Processing: Syed Hunain Riaz, Analysis or Interpretation: Syed Hunain-Riaz/Ali Jawa, Literature Search: Syed Hunain Riaz/Ali Jawa, Writing: Syed Hunain Riaz/Ali Jawa.

Conflict of Interest: No conflict of interest was declared by the authors.

Financial Disclosure: The authors declared that this study received no financial support.

References

1. Sewerynek E, Stuss M. Steroid-induced osteoporosis. *Aging Health*. 2012;8:471-477.
2. Angeli A, Guglielmi G, Dovio A, Capelli G, de Feo D, Giannini S, Giorgino R, Moro L, Giustina A. High prevalence of asymptomatic vertebral fractures in post-menopausal women receiving chronic glucocorticoid therapy: a cross-sectional outpatient study. *Bone*. 2006;39:253-259.
3. Shaker JL, Lukert BP. Osteoporosis associated with excess glucocorticoids. *Endocrinol Metab Clin North Am*. 2005;34:341-356.
4. Lee YL, Yip KM. The osteoporotic spine. *Clin Orthop Relat Res*. 1996;323:91-97.
5. Wong CA, Walsh LJ, Smith CJ, Wisniewski AF, Lewis SA, Hubbard R, Cawte S, Green DJ, Pringle M, Tattersfield AE. Inhaled corticosteroid use and bone-mineral density in patients with asthma. *Lancet*. 2000;355:1399-1403.
6. Allen DB, Bielory L, Derendorf H, Dluhy R, Colice GL, Szeffler SJ. Inhaled corticosteroids: past lessons and future issues. *J Allergy Clin Immunol*. 2003;112:S1-40.
7. van Staa TP, Leufkens HG, Cooper C. The epidemiology of corticosteroid-induced osteoporosis: a meta-analysis. *Osteoporos Int*. 2002;13:777-787.
8. Canalis E, Mazziotti G, Giustina A, Bilezikian JP. Glucocorticoid-induced osteoporosis: pathophysiology and therapy. *Osteoporos Int*. 2007;18:1319-1328.
9. Wong GL. Basal activities and hormone responsiveness of osteoclast-like and osteoblast-like bone cells are regulated by glucocorticoids. *J Biol Chem*. 1979;254:6337-6340.
10. Sasaki N, Kusano E, Ando Y, Yano K, Tsuda E, Asano Y. Glucocorticoid decreases circulating osteoprotegerin (OPG): possible mechanism for glucocorticoid induced osteoporosis. *Nephrol Dial Transplant*. 2001;16:479-482.
11. van Staa TP, Leufkens HG, Cooper C. Does a fracture at one site predict later fractures at other sites? A british cohort study. *Osteoporos Int*. 2002;13:624-629.
12. Van Staa TP, Leufkens HG, Abenham L, Zhang B, Cooper C. Use of oral corticosteroids and risk of fractures. *J Bone Miner Res*. 2000;15:993-1000.
13. Decramer M, Rennard S, Troosters T, Mapel DW, Giardino N, Mannino D, Sethi S, Cooper CB. COPD as a lung disease with systemic consequences--clinical impact, mechanisms, and potential for early intervention. *COPD*. 2008;5:235-256.
14. Vestergaard P. Changes in bone turnover, bone mineral and fracture risk induced by drugs used to treat epilepsy. *Curr Drug Saf*. 2008;3:168-172.
15. Taggart HM, Tweedie DR. Spinal cord compression: remember osteoporosis. *Br Med J (Clin Res Ed)*. 1987;294:1148-1149.
16. Salomon C, Chopin D, Benoist M. Spinal cord compression: an exceptional complication of spinal osteoporosis. *Spine (Phila Pa 1976)*. 1988;13:222-224.
17. Demir SO, Akin C, Aras M, Köseoğlu F. Spinal cord injury associated with thoracic osteoporotic fracture. *Am J Phys Med Rehabil*. 2007;86:242-246.
18. O'Connor PA, Eustace S, O'Byrne J. Spinal cord injury following osteoporotic vertebral fracture: case report. *Spine (Phila Pa 1976)*. 2002;27:E413-415.
19. Heggness MH. Spine fracture with neurological deficit in osteoporosis. *Osteoporos Int*. 1993;3:215-221.
20. Baba H, Maezawa Y, Kamitani K, Furusawa N, Imura S, Tomita K. Osteoporotic vertebral collapse with late neurological complications. *Paraplegia*. 1995;33:281-289.
21. Baig MA, Anjum MP, Khani MK, Islam N, Rahman A. Pattern of serum Vitamin D in OPD patients. *Pak J Surg*. 2007;23:145-149.
22. Holick MF. Optimal vitamin D status for the prevention and treatment of osteoporosis. *Drugs Aging*. 2007;24:1017-1029.
23. Johnell O, Gullberg B, Kanis JA, Allander E, Elffors L, Dequeker J, Dilsen G, Gennari C, Lopes Vaz A, Lyritis G. Risk factors for hip fracture in European women: the MEDOS study. *J Bone Miner Res*. 1995;10:1802-1815.