



# Clinical Value of Histogram Analysis Using Gray-Scale Ultrasound Images in Thyroiditis

## Tiroiditlerde Gri Skala Ultrason Görüntülerinin Histogram Analizinin Klinik Değeri

<sup>ID</sup> Hatice Ayça Ata Korkmaz, <sup>ID</sup> Mustafa Köse\*

Health Science University, Kanuni Research and Education Hospital, Clinic of Radiology, Trabzon, Turkey

\* Health Science University, Kanuni Research and Education Hospital, Clinic of Endocrinology and Metabolism, Trabzon, Turkey

### Abstract

**Objective:** The main purpose of this study was to investigate the histogram analysis (HA) in terms of the differential diagnosis of thyroiditis.

**Material and Methods:** A total of 137 cases with a definitive diagnosis of thyroiditis confirmed with clinical and laboratory findings were evaluated in the study. Out of these, 23 cases were diagnosed as Graves' disease (GD), 94 as Hashimoto's thyroiditis (HT), and 20 as subacute thyroiditis (SAT), and 34 healthy volunteers were included in this study as a control group. The thyroid and sternocleidomastoid muscle's (SCM) HA and thyroid-to-SCM echogenicity ratio (TRSCMR) were evaluated.

**Results:** The HA values of thyroid parenchyma and SCM (mean±SD) of patients with GD, HT, SAT, and CG were 83.49±27.91, 71.25±20.93, 70.83±13.94, and 80.95±20.88, and 52.74±24.11, 58.17±18.67, 67.20±14.71, and 69.32±18.94, respectively. The HAs of thyroid parenchyma of GD, HT, and SAT were not statistically significant. The TRSCMR (mean±SD) of patients with GD, HT, SAT, and CG were 1.85±0.86, 1.29±0.41, 1.09±0.26, and 1.25±0.5, respectively. Compared with the control group, the GD TRSCMRs were higher than the CG TRSCMRs ( $p<0.0001$ ). Compared with SAT, GD TRSCMRs were higher than SAT TRSCMRs, and these results were statistically significant ( $p<0.001$ ).

**Conclusion:** This study demonstrated that HA may help in differentiating SAT from GD that show similar appearance on routine ultrasonography.

**Keywords:** Histogram analysis; subacute thyroiditis; Hashimoto's thyroiditis; Graves' disease; thyroid ultrasonography

### Özet

**Amaç:** Bu çalışmanın temel amacı tiroiditlerin ayırıcı tanısında histogram analizinin (HA) yerini araştırmaktır.

**Gereç ve Yöntemler:** Klinik ve laboratuvar bulgularıyla tiroidit tanısı kesinleşmiş 137 olgu çalışmaya dahil edildi. Olguların 23'ü Graves Hastalığı (GH), 94 hasta Hashimoto tiroiditi (HT), 20'si ise Subakut Tiroidit (SAT) tanısı almıştı. Sağlıklı 34 gönüllü ise kontrol grubu (KG) olarak çalışmaya dahil edildi. Tiroid ve sternocleidomastoid kası (SCM) histogram analizleri ile tiroid parankim ekosunun SCM ekosuna oranı (TRSCMR) değerlendirildi.

**Bulgular:** GH, HT, SAT, KG olgularının tiroid parankimi ve SCM HA (ortalama± SD) değerleri sırasıyla 83.49 ±27.91, 71.25±20.93, 70.83±13.94, 80.95±20.88 ve 52.74±24.11, 58.17±18.67, 67.20±14.71, 69.32±18.94 şeklindedir. GH, HT ve SAT tiroid parankim HA değerleri arasında istatistiksel olarak anlamlı fark yoktu. GH, HT, SAT ve KG'nun TRSCMR (ortalama ± SD) değerleri sırasıyla 1.85±0.86, 1.29±0.41, 1.09±0.26 and 1.25±0.5'dir. Kontrol grubu ile karşılaştırıldığında GH TRSCMR değerleri KG TRSCMR değerlerinden yüksek, SAT grubunun TRSCMR değerleri ise KG grubunun TRSCMR değerlerinden düşük olup, istatistiksel olarak anlamlıydı ( $p<0.05$ ). SAT ve GH tiroiditlerinin TRSCMR değerleri karşılaştırıldığında, GH TRSCMR değerleri SAT TRSCMR değerlerinden yüksek olup, istatistiksel olarak anlamlıydı ( $p=0.001$ ).

**Sonuç:** Çalışmamız, ultrasonografide benzer görüntüleme özelliklerine sahip SAT ve GH' nin ayırıcı tanısının yapılmasında histogram analizinin faydalı olabileceğini göstermiştir.

**Anahtar kelimeler:** Histogram analizi; subakut tiroidit; Hashimoto tiroiditi; Graves hastalığı; tiroid ultrasonografisi

### Introduction

Diffuse thyroid diseases include hyperthyroidism, chronic autoimmune hyperthyroidism (Hashimoto's

thyroidism [HT]), subacute thyroiditis (SAT), and Graves' disease (GD). The imaging features of thyroid parenchyma echogenicity are used in B-mode

**Address for Correspondence:** Hatice Ayça Ata Korkmaz, Health Science University, Kanuni Research and Education Hospital, Clinic of Radiology, Trabzon, Turkey

**Phone:** +90 462 341 56 56 **E-mail:** dr.h.aycaatakorkmaz@gmail.com **Received:** 21/11/2017 **Accepted:** 10/01/2018

©Copyright 2018 by Turkish Journal of Endocrinology and Metabolism Association  
Turkish Journal of Endocrinology and Metabolism published by Türkiye Klinikleri

imaging in the differential diagnosis of thyroiditis. However, this differentiation is subjective and depends on the examiner. The differentiation of GD and SAT in gray-scale sonograms is difficult because of their similar appearances. Although they share similar clinical, biochemical, and sonographic properties, they have different etiopathogenesis and require different treatments. Therefore, a correct diagnosis of these types of thyroiditis by ultrasonography is critical. Ultrasound assessment has limited value in terms of the differential diagnosis of thyroiditis. Therefore, radiological imaging techniques may have to be developed to provide crucial information to clinicians for planning treatment algorithms.

With the developing technology, computer programs may be able to diagnose diseases similar to a radiologist in the near future. Therefore, the quantitative B-mode evaluation methods should be developed. In this study, we aimed to investigate the use of histograms in diagnosing thyroiditis.

Palpation has long been used for the examination of the thyroid. Sonoelastography (USE), first used by Ophir et al., has replaced palpation in the examination of thyroid (1). The current literature reported the use of USE in thyroiditis by a shear wave and strain elastography (1-6). However, elastography is a new developing technology that is not currently available in several ultrasonic devices, and the contribution of the differential diagnosis of thyroiditis remains unclear.

In addition, gray-scale ultrasound imaging is a universal and easily accessible technology worldwide. Thus, new evaluation techniques should be developed for accurate diagnosis and treatment. Histogram analysis (HA) is based on the recordings of images obtained in the ultrasonographic gray-scale mode, and these images are analyzed with a special medical software program after they are transferred to a workstation.

The HA of gray-scale ultrasound images has been investigated in various organs for the differentiation of transudate from exudative ascites, breast tumor differentiation, perfusion defects of kidney disease, characterization of parathyroid gland injury after head-and-neck radiotherapy, differentiation of asymptomatic diffuse thyroid disease from normal thyroid, and investigation of the chronic thyroiditis appearance (7-15).

Despite the benefits of HA in chronic thyroiditis, data regarding the use of HA in SAT, HT, and GD are limited (12-15). The capability of differential diagnosis by HA and thyroid-to-sternocleidomastoid

muscle echogenicity ratio (TRSCMR) in thyroiditis is yet to be investigated. In this study, we aimed to investigate the applicability of HA and TRSCMR in different types of thyroiditis.

### Graves' Disease

GD is an autoimmune condition that presents with thyrotoxicosis induced by circulating thyroid-stimulating hormone receptor autoantibodies (TRAbs) with thyroid-stimulating activity. In addition, thyrotoxicosis is the result of different types of painless thyroiditis. To identify the exact cause of thyrotoxicosis, radioactive iodine uptake measurement is still the gold standard of clinical application. By contrast, nuclear medicine techniques are unavailable in several health facilities, though radioactive substances are contraindicated for lactating and pregnant women.

The prevalence of GD is 5 to 10 times more common in females than in males. The maximum incidences of the disease were observed during the third to sixth decades. Tremor, heat intolerance, nervousness, weight loss, goiter, fatigue, tachycardia, and exophthalmos are the most usual clinical symptoms of GD. The evaluation of TRAb levels in the blood is advantageous for differentiating GD from HT and SAT. However, TRAb analyses are not accessible in general hospitals and clinics.

Ultrasonography is a non-invasive and cost-effective imaging technique for the examination of the thyroid parenchyma. GD is identified using B-mode ultrasonography through the development of diffuse thyroid enlargement with the loss of echogenicity. In addition, it is associated with the increased intraparenchymal thyroidal flow on color flow Doppler sonography (16).

The increased thyroid vascularity is crucial evidence for GD, which is beneficial for differentiating GD from SAT and HT (17).

In theory, the differential diagnosis of GD from SAT and HT by HA is possible because of the different histopathologic characteristics and types of thyroid gland vascularities for each condition. To date, no study has compared the TRSCMRs among patients with GD and other types of thyroiditis.

### Subacute Thyroiditis

SAT is an unusual, self-limiting condition that generally occurs after an upper tract viral infection, which is the result of an autoimmune response (18). Clinically, this situation is associated with severe anterior neck pain and may radiate

up to the mandible, ear, and occipital fossa. At the beginning of this condition, SAT usually causes low-grade fever with thyrotoxicosis (19). The laboratory findings of SAT have decreased thyrotropin levels, increased thyroid hormones (FT4 and FT3), and increased C-reactive protein (20).

In general, the gray-scale and Doppler sonographic findings of SAT are thyroid enlargement and ill-defined focal hypoechoic areas with hypovascularity (19). After treatment, these findings usually disappear (19).

### Hashimoto's Thyroiditis

HT is the most usual inflammatory process of the thyroid gland, and it is the main cause of autoimmune hypothyroidism. This condition develops 15 times more in women than in men. The maximum incidences of HT were observed during the third to fifth decades (21). The prevalence of HT is approximately 5% to 15% in women. HT is commonly associated with the development of circulating anti-thyroid autoantibodies, which are the cause of cytological injury and thyroid malfunction. The detection of thyroglobulin antibody and/or thyroid peroxidase antibody in blood tests is used for the diagnosis of HT. Ultrasonography shows the loss of echogenicity, increased heterogeneity, and decreased normal vascularity with the development of septa and hypoechoic micronodules in the patients with HT (22).

The degree of thyroid fibrosis is associated with decreased echogenicity in HT. The applicability of HT for the evaluation of thyroid HA was first described by Schiemann et al. in 2003 (14).

## Material and Methods

### Study Population

Most of the patients were sampled from the patient population treated in the Department of Endocrinology at Trabzon Kanuni Research and Education Hospital, between November 2015 and January 2017. The patients with a suspected diagnosis of thyroiditis were identified. The patients under 18 years and above 90 years of age or without available images (B-mode ultrasonography) and laboratory tests were excluded. In addition, the patients who were diagnosed with thyroiditis were excluded.

The study was approved by the local institutional review board and all participants provided written informed consent. This prospective, single-insti-

tution study was conducted in compliance with the Helsinki Declaration and good clinical practice guidelines of the Ministry of Health of Turkey. The study was approved by the local ethics committee of Kanuni Research and Education Hospital, Turkey.

An Aplio 500 ultrasound machine (Toshiba Medical Systems, Co. Ltd., Otawara, Japan) with linear 4.8 to 11 MHz transducers and elastography software was used. All the examinations were performed by one radiologist with an experience of more than 15 years in thyroid imaging. The radiologist was blinded to the clinical findings, laboratory results, early clinical suspected differential diagnosis of thyroiditis, and the final diagnosis of the patients. A total of 250 individuals examined in our radiology department from October 2015 to March 2016 were screened. Out of these individuals, 52 patients were having thyroid nodules in addition to thyroiditis, which were detected incidentally. High-quality images were not obtained from 17 patients because of retrosternal thyroid enlargement or short neck anatomical structure. A total of 69 patients were excluded from the study. Finally, 171 cases were included in the study. Out of these cases, 23 were diagnosed as GD (8 men, 15 women;  $33 \pm 12$  years), 94 were diagnosed as HT (8 men, 86 women;  $40 \pm 13$  years), and 20 were diagnosed as SAT (8 men, 12 women;  $42 \pm 9$  years). All cases were confirmed by clinical examination and laboratory findings. The control group (CG) consisted of 34 healthy volunteers (5 men, 29 women;  $40 \pm 10$  years) whose ultrasound imaging and thyroid laboratory results were normal (Table 1).

### Ultrasound Imaging

The ultrasound examination started with gray-scale imaging. The patient was supine with a slightly hyperextended position over a special wheeled bed, which was built for thyroid imaging. The B-mode ultrasonographic evaluation of thyroid glands was performed with standard transverse and longitudinal planes. In addition, thyroid dimensions and parenchymal echogenicity were evaluated. The echogenicity of the thyroid parenchyma was defined as marked hypoechoogenicity, isoechoogenicity, and hyperechoogenicity.

Thyroid echogenicity was evaluated by comparing neighboring neck muscles (23). During the gray-scale ultrasound, all thyroid regions suspected for thyroiditis were identified in a longitudinal scanning position.

Table 1. The analysis of the study population.

Variable	CG n (%)	Number of cases			P value
		HT n (%)	SAT n (%)	GD n (%)	
	<b>34 (19,9)</b>	<b>94 (55,0)</b>	<b>20 (11,7)</b>	<b>23 (13,5)</b>	
Female	29 (20,4)	86 (60,6)	12 (8,5)	15 (10,5)	0.001
Male	5 (17,2)	8 (27,6)	8 (27,6)	8 (27,6)	0.001
Age	40.3±10.2	40.1±13.0	42.2±9.2	33.3±12.1	0.457

CG: Control group; HT: Hashimoto's thyroiditis; SAT: Subacute thyroiditis; GD: Graves' disease; ns: Nonsignificant.

Before saving the image in the JPEG format in ultrasound database, we checked that the selected B-mode image does not contain any thyroid nodules and lymph nodes. If necessary, patients were requested to hold their breath to prevent gray-scale artifacts.

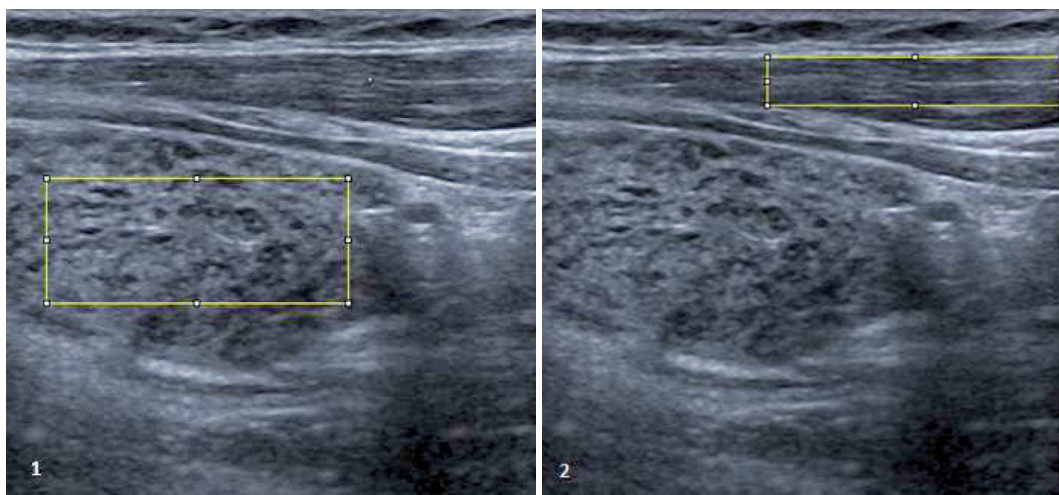
To improve and standardize the imaging quality, we selected gray-scale time-gain compensation values between -30 and 30 dB and gain levels between 0 and 60. Finally, the focus-level interval was from 0 to 4, and we used focus level 2. We obtained three sonographic images for each of the thyroid gland and sternocleidomastoid muscle (SCM). After the examination, we selected the technically perfect image from the collected data for HA. This selected JPEG was considered valid.

### Histogram Image Analysis

Electronically recorded sonographic data in the JPEG format were transferred to a high-resolu-

tion computer system, and ImageJ software (version 1.4.3.67, National Institutes of Health) was used for gray-scale HA. The echogenicity of the images was measured as gray-scale pixels ranging from 0 to 255 (0=black, 255=white) through HA.

A region of interest (ROI) for HA was identified. The ROI included maximum possible thyroid lobes that were affected from thyroiditis to investigate a maximal amount of the thyroid parenchyma (Figure 1). The first ROI was accepted as the target region. We then selected another ROI as a reference. The ipsilateral SCM was selected for comparing the affected thyroiditis area to depict color pixels (Figure 2). Both ROIs included maximum possible thyroid tissue and SCM. In addition, we ensured that both ROIs were placed at the same vertical axis to the transducer and in the central region of the image. The TRSCMR was obtained from the collected data.



**Figure 1, 2:** Grayscale evolution method for the Histogram Analysis of thyroidal parenchyma. Two ROIs for comparison were delineated to calculate the SR. The big rectangle (target) A is the local ROI on the thyroid tissue, the small rectangle (reference) B is the local ROI on the sternocleidomastoid in front of the ipsilateral thyroid.



## Statistical Analysis

Continuous variables were expressed as mean±standard deviation (SD), and categorical variables were expressed in percentages. The normality of the continuous variables was analyzed using the Kolmogorov-Smirnov test. The categorical variables between the groups were compared using the chi-square test. The numerical variables between independent groups were compared. If the normal distribution requirement was provided, then analysis of variance was performed. If the normal distribution requirement was not provided, then Kruskal-Wallis variance analysis was used. The Mann-Whitney U test was performed to determine whether the distribution of thyroid and SCM HA and TRSCMR is different among CG, SAT, GD, and HT. In addition, the Mann-Whitney U test was used to compare the HAs and TRSCMRs of the groups. The receiver operating characteristic curve was used to determine the cut-off point of the HA and TRSCMR of normal and experimental subjects. The p-values lower than 0.05 were considered statistically significant. In the presence of a significant threshold, sensitivity, and specificity values were calculated. To evaluate the area under the curve (AUC), the diagnostic value of the test was accepted as statistically significant when type 1 error was less than 5%. The statistical analysis was performed using SPSS 22.0 statistical software (24).

## Results

The clinical and demographic characteristics of patients are shown in Table 1.

The HA values of thyroid parenchyma (mean±SD) of patients with GD, HT, SAT, and CG were 83.49±27.91, 71.25±20.93, 70.83±13.94, 80.95±20.88, and 52.74±24.11, respectively. By contrast, the HA values of SCM (mean±SD) of patients with GD, HT, SAT, and CG were 52.74±24.11, 58.17±18.67, 67.20±14.71, and 69.32±18.94, respectively (Table 2).

The thyroid parenchyma HAs of GD, HT, and SAT were not statistically significant, whereas SCM HA values of HT and GD were statistically significant (p=0.009).

The TRSCMR (mean±SD) of patients with GD, HT, SAT, and CG were 1.85±0.86, 1.29±0.41, 1.09±0.26, and 1.25±0.5, respectively (Table 3 and Figures 3–5).

Compared with the CG, patients with GD had statistically significant TRSCMRs (p=0.001).

TRSCMRs presented the following ascending order: SAT<CG<HT<GD. The boxplot of the TRSCMR values to each group is shown in Figure 6. Patients with GD had statistically different TRSCMRs (p=0.001) compared with patients with SAT. This result is noteworthy because SAT and GD share similar imaging properties in gray-scale sonography. The cut-off points of the TRSCMR of patients with GD, HT, and SAT to the CG were 1.32 (sensitivity

Table 2. The distributions of HA results of thyroidal parenchyma (TP) and SCM.

Group	Number of cases n (%)	Mean±SD (TP)	Mean±SD (SCM)
CG	34 (19,88)	80,95 (20,88)	69,32 (18,94)
HT	94 (54,98)	71,25 (20,93)	58,17 (18,67)
SAT	20 (11,69)	70,83 (13,94)	67,20 (14,71)
GD	23 (13,45)	83,49 (27,91)	52,74 (24,11)
TOTAL	171 (100.0)		

CG: Control group; HT: Hashimoto's thyroiditis; SAT: Subacute thyroiditis; GD: Graves' disease.

Table 3. Thyroid and sternocleidomastoideus muscle ratio (TRSCMR) ranges of different groups.

Group	Number of cases n (%)	TRSCMRs		
		Range	Median	Mean ±SD
CG	34 (19,88)	0,64–2,22	1,17	1,25 ±0,5
HT	94 (54,98)	0,61–2,65	1,22	1,29 ±0,41
SAT	20 (11,69)	0,69–1,25	1,02	1,09 ±0,26
GD	23 (13,45)	1,48–2,23	1,61	1,85 ±0,86
Total	171 (100.0)			

CG: Control group; HT: Hashimoto's thyroiditis; SAT: Subacute thyroiditis; GD: Graves' disease.

Table 4. TRSCMR's for differential diagnosis of thyroiditis and CG for different groups with the standard errors and 95% Confidence limits for the AUC.

Group	95% CI	Std. Error	AUC	p values
GD-CG	0,589-0,833	0,062	0.711	0,0001
SAT-CG	0,250-0,459	0,053	0,354	0,667
HT-CG	0,411-0,590	0,045	0,500	0,975
GD-SAT	0,651-0,932	0,072	0,791	0,001

CG: Control group; HT: Hashimoto's thyroiditis; SAT: Subacute thyroiditis; GD: Graves' disease; TRSCMR: Thyroid and sternocleidomastoideus muscle ratio; AUC: Area under the curve; CI: Confidence limits.

74%, specificity 66%, AUC 0.711), 1.74 (sensitivity 96%, specificity 77%, AUC 0.500), and 1.74 (sensitivity 100%, specificity 84%, AUC 0.354), respectively. To determine a cut-off point for differentiation, the two most interfering groups in B-mode imaging were SAT and GD. HT and CG were excluded. The cut-off point of the TRSCMR of patients with GD to the SAT was 3.34 (sensitivity 87%, specificity 100%, AUC 0.791; Table 4 and Figure 7).

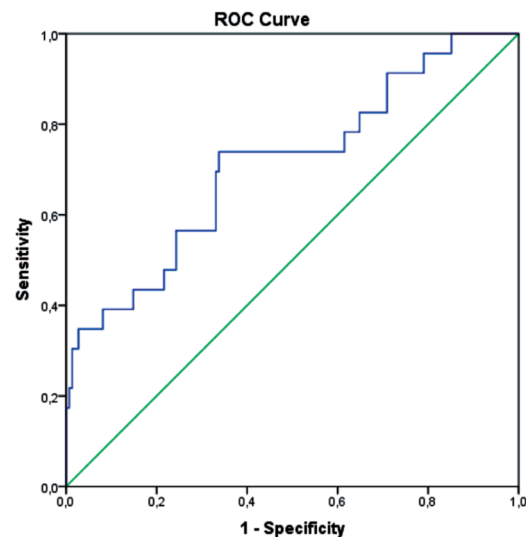
## Discussion

In this study, we performed the B-mode HA of thyroid parenchyma using sonography and evaluated its applicability to differentiate thyroiditis from healthy thyroid and the subtypes of thyroiditis from one another.

We found statistically significant values in TRSCMRs in GD compared with other types of thyroiditis, indicating that TRSCMRs can be used as a supplementary sonographic parameter. Compared with the CG, the GD TRSCMR values were higher than the CG TRSCMR values and the TRSCMR values of the SAT group were lower than the TRSCMR values of the CG group, which was statistically significant ( $p < 0.0001$ ).

GD is an autoimmune condition that presents with thyrotoxicosis, which can also be the result of different types of thyroiditis. To identify the exact cause of thyrotoxicosis, the radioactive iodine uptake measurement is still the gold standard of clinical application. GD shows radioactive iodine uptake even when SAT does not. By contrast, nuclear medicine techniques are not easily accessible at several health centers, and radioactive materials are harmful to lactating and pregnant women. GD's gray-scale sonographic features are thyroid enlargement with the loss of parenchymal echogenicity.

SAT is an unusual, self-limiting condition that generally develops after an upper tract infection caused by a viral infection, which is the result of



**Figure 3:** The receiver operating characteristic curve of TRSCMRs for differential diagnosis of the group of GD and the control group.

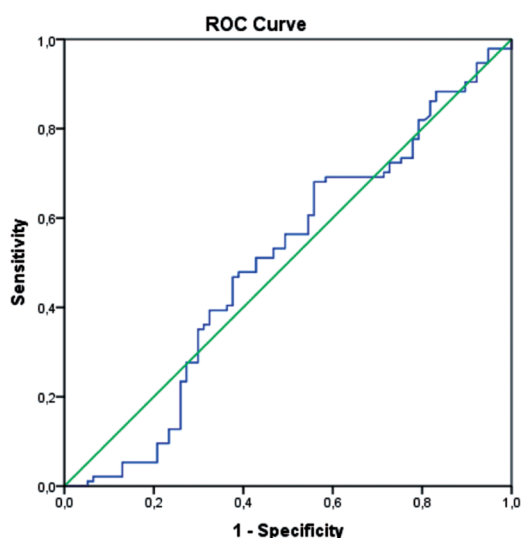
The diagonal segment is produced by ties.

an autoimmune response (18). Initially, SAT usually causes low-grade fever with thyrotoxicosis (19).

In general, the gray-scale sonographic findings of SAT are thyroid enlargement and ill-defined focal hypoechoic areas (19).

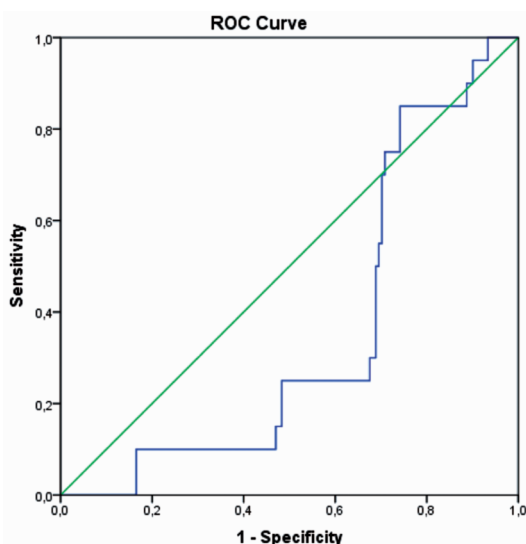
The gray-scale ultrasound findings of SAT and GD are highly similar. Our study results revealed that the gray-scale sonographic imaging findings of SAT and GD showed no statistically significant differences ( $p = 0.215$ ).

The treatment of SAT and GD depends on their etiopathogenesis and is completely different. Non-steroidal anti-inflammatory drugs and corticosteroids are used in SAT treatment, whereas anti-thyroid-acting propylthiouracil and thiamazole are used in GD treatment. Discriminant diagnosis must be performed correctly, as they have different treatments.



**Figure 4:** Receiver operating characteristic curve of TRSCMRs for differential diagnosis of the group of Hashimoto's thyroiditis and the control group.

The diagonal segment is produced by ties.



**Figure 5:** Receiver operating characteristic curve of TRSCMRs for differential diagnosis of the group of SAT and the control group.

The diagonal segment is produced by ties.

In theory, the differential diagnosis of GD from SAT and HT by HA is possible because of the different histopathologic characteristics and types of thyroid gland vascularities for each condition. To date, no study has compared the TRSCMRs among patients with GD and other types of thyroiditis.

In this study, GD TRSCMR values were higher than SAT TRSCMR values. TRSCMRs could statistically significantly differentiate GD from SAT; however, it could not differentiate SAT from HT and CG. This result was particularly remarkable because SAT and GD have similar imaging properties to gray-scale sonography.

The applicability of HA for the evaluation of chronic thyroiditis was first described by Schiemann et al. in 2003 (14). The current studies focused on ultrasound gray-scale HA in chronic thyroiditis (12-15,25). These studies are based on thyroid parenchymal HA rather than TRSCMR. Conversely, conventional ultrasound is a worldwide, easily accessible, inexpensive, and innocuous diagnostic method. However, ultrasound is a user-dependent imaging modality, which is the most crucial disadvantage for technique standardization. Kim et al. showed that even if experienced radiologists identify the presence of chronic thyroiditis based on the specific similar sonographic features of HT, their evaluations are inconsistent (25).

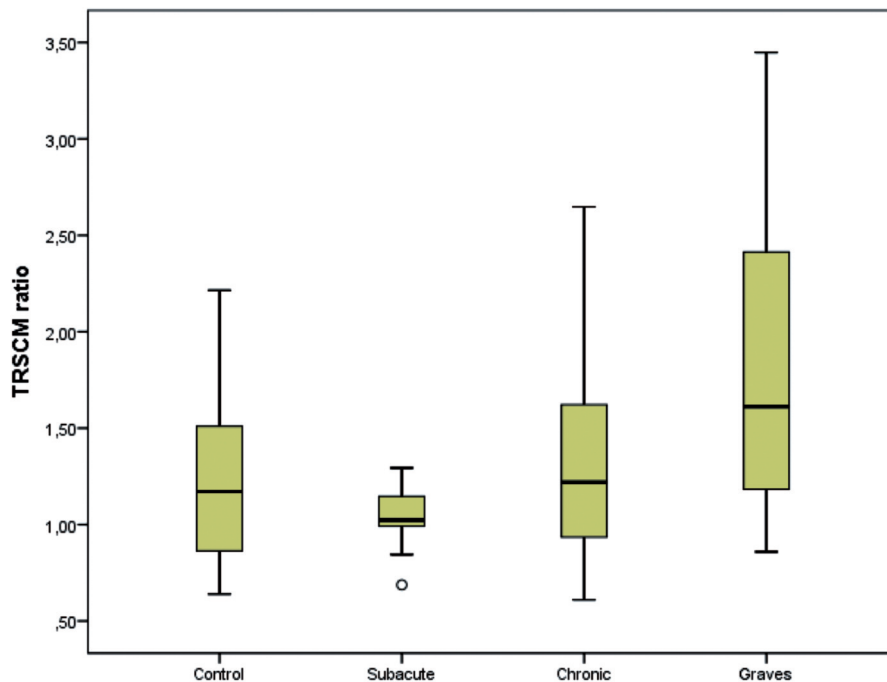
SAT is a painful and inflammatory condition (26). Pain may be bilateral or unilateral and spread to the mandible, occipital fossa, and ear. Researchers must realize that patients may choose to avoid neck movements to prevent pain, and this option may lead to an increase in muscle echogenicity. In this study, statistically significant TRSCMR differentiating SAT from GD was a result of increased muscle echogenicity in SAT, which was secondary to immobilization and decreased muscle echogenicity in GD because of the increased vascularity.

This study had some limitations. First, the gender of enrolled patients was not equal because of the nature of thyroiditis. Second, cytological findings for each of the thyroiditis groups and long-term follow-up HA values after treatment were not included.

Further studies in the recovery phase of thyroiditis are required to enrich the findings of this study.

## Conclusion

The HA of sonographic imaging is applicable for differentiating patients with thyroiditis from healthy individuals; however, its differentiating value for different types of thyroiditis, such as SAT and HT, is limited. TRSCMR is valuable for differentiating patients with thyroiditis from healthy individuals; however, it has limited value in differentiating SAT-HT from GD-HT. Our study



**Figure 6:** Boxplot of strain ratios in different groups.

GH TRSCMR values were higher than SAT TRSCM values and these results were statistically significant ( $p < 0.001$ ).

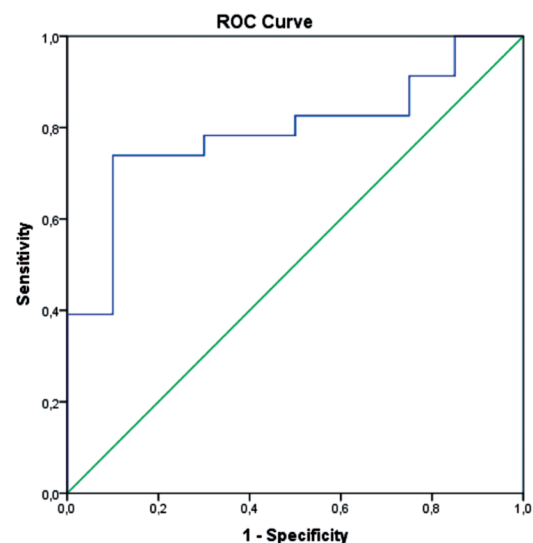
results revealed that TRSCMR was the only useful method for differentiating GD from SAT. TRSCMR is a useful method for the differential diagnosis of GD from a healthy population or from SAT.

HA would be useful in differentiating GD from other causes of hyperthyroidism to avoid overtreating SAT and provide a prognosis. Nuclear medicine studies may confirm this role; however, they involve radiation and are not always available. In addition, laboratory tests are useful but not always available.

HA combined with conventional ultrasonography is an excellent tool for the discrimination of GD from SAT.

**Source of Finance:** During this study, no financial or spiritual support was received neither from any pharmaceutical company that has a direct connection with the research subject, nor from a company that provides or produces medical instruments and materials which may negatively affect the evaluation process of this study.

**Conflict of Interest:** No conflicts of interest between the authors and / or family members of the scientific and medical committee members or members of the potential conflicts of interest, counseling, expertise, working conditions, share holding and similar situations in any firm.



**Figure 7:** Receiver operating characteristic curve of TRSCMRs for differential diagnosis of the group of GD and SAT.

The diagonal segment is produced by ties.

### Authorship Contributions

Idea/Concept: Hatice Ayça Ata Korkmaz; Design: Hatice Ayça Ata Korkmaz; Control/Supervision: Mustafa Köse; Data Collection And/Or Processing: Mustafa Köse; Analysis and/or Interpreta-



tion: Hatica Ayça Ata Korkmaz; Literature Review: Hatica Ayça Ata Korkmaz; Writing the Article: Hatica Ayça Ata Korkmaz; Critical Review: Mustafa Köse; Materials: Mustafa Köse, Hatica Ayça Ata Korkmaz.

## References

- Ophir J, Céspedes I, Ponnekanti H, Yazdi Y, Li X. Elastography: a quantitative method for imaging the elasticity of biological tissues. *Ultrason Imaging*. 1991;13:111-134.
- Ruchala M, Szczepanek-Parulska E, Zybek A, Moczko J, Czarnywojtek A, Kaminski G, Sowinski J. The role of sonoelastography in acute, subacute and chronic thyroiditis: a novel application of the method. *Eur J Endocrinol*. 2012;166:425-432.
- Menzilcioglu MS, Duymus M, Gungor G, Citil S, Sahin T, Boysan SN, Sarica A. The value of real-time ultrasound elastography in chronic autoimmune thyroiditis. *Br J Radiol*. 2014;87:20140604.
- Kim I, Kim EK, Yoon JH, Han KH, Son EJ, Moon HJ, Kwak JY. Diagnostic role of conventional ultrasonography and shearwave elastography in asymptomatic patients with diffuse thyroid disease: initial experience with 57 patients. *Yonsei Med J*. 2014;55:247-253.
- Ruchala M, Szmyt K, Sławek S, Zybek A, Szczepanek-Parulska E. Ultrasound sonoelastography in the evaluation of thyroiditis and autoimmune thyroid disease. *Endokrynol Polska*. 2014;65:520-531.
- Yang Z, Zhang H, Wang K, Cui G, Fu F. Assessment of diffuse thyroid disease by strain ratio in ultrasound elastography. *Ultrasound Med Biol*. 2015;41:2884-2889.
- Çekiç B, Toslak IE, Şahintürk Y, Çekin AH, Koksul YK, Koroglu M, Demos TC. Differentiating transudative from exudative ascites using quantitative B-mode gray-scale ultrasound histogram. *AJR Am J Roentgenol*. 2017;209:313-319.
- Erol B, Kara T, Gürses C, Karakoyun R, Köroğlu M, Süren D, Bülbüller N. Gray scale histogram analysis of solid breast lesions with ultrasonography: can lesion echogenicity ratio be used to differentiate the malignancy? *Clin Imaging*. 2013;37:871-875.
- Rossi C, Artunc F, Martirosian P, Schlemmer HP, Schick F, Boss A. Histogram analysis of renal arterial spin labeling perfusion data reveals differences between volunteers and patients with mild chronic kidney disease. *Invest Radiol*. 2012;47:490-496.
- Yang X, Tridandapani S, Beitler JJ, Yu DS, Yoshida EJ, Curran WJ, Liu T. Ultrasound histogram assessment of parotid gland injury following head-and-neck radiotherapy: a feasibility study. *Ultrasound Med Biol*. 2012;38:1514-1521.
- Kim DW, Eun CK, In HS, Kim MH, Jung SJ, Bae SK. Sonographic differentiation of asymptomatic diffuse thyroid disease from normal thyroid: a prospective study. *AJNR Am J Neuroradiol*. 2010;31:1956-1960.
- Mazziotti G, Sorvillo F, Iorio S, Carbone A, Romeo A, Piscopo M, Capuano S, Capuano E, Amato G, Carella C. Grey-scale analysis allows a quantitative evaluation of thyroid echogenicity in the patients with Hashimoto's thyroiditis. *Clin Endocrinol (Oxf)*. 2003;59:223-229.
- Acharya UR, Vinitha Sree S, Mookiah MR, Yantri R, Molinari F, Zieleznik W, Malyszek-Tumidajewicz J, Stępień B, Bardales RH, Witkowska A, Suri JS. Diagnosis of Hashimoto's thyroiditis in ultrasound using tissue characterization and pixelclassification. *Proc Inst Mech Eng H*. 2013;227:788-798.
- Schiemann U, Avenhaus W, Konturek JW, Gellner R, Hengst K, Gross M. Relationship of clinical features and laboratory parameters to thyroid echogenicity measured by standardized grey scale ultrasonography in patients with Hashimoto's thyroiditis. *Med Sci Monit*. 2003;9:MT13-17.
- Loy M, Cianchetti ME, Cardia F, Melis A, Boi F, Mariotti S. Correlation of computerized gray-scale sonographic findings with thyroid function and thyroid autoimmune activity in patients with Hashimoto's thyroiditis. *J Clin Ultrasound*. 2004;32:136-140.
- Cappelli C, Pirola I, De Martino E, Agosti B, Delbarba A, Castellano M, Rosei EA. The role of imaging in Graves' disease: a cost-effectiveness analysis. *Eur J Radiol*. 2008;65:99-103.
- Bogazzi F, Bartalena L, Brogioni S, Burelli A, Manetti L, Tanda ML, Gasperi M, Martino E. Thyroid vascularity and blood flow are not dependent on serum thyroid hormone levels: studies in vivo by color flow doppler sonography. *Eur J Endocrinol*. 1999;140:452-456.
- Omori N, Omori K, Takano K. Association of the ultrasonographic findings of subacute thyroiditis with thyroid pain and laboratory findings. *Endocr J*. 2008;55:583-588.
- Park SY, Kim EK, Kim MJ, Kim BM, Oh KK, Hong SW, Park CS. Ultrasonographic characteristics of subacute granulomatous thyroiditis. *Korean J Radiol*. 2006;7:229-234.
- Benker G, Olbricht T, Windeck R, Wagner R, Albers H, Lederbogen S, Hoff HG, Reinwein D. The sonographical and functional sequelae of de Quervain's subacute thyroiditis: long-term follow-up. *Acta Endocrinol (Copenh)*. 1988;117:435-441.
- Pearce EN, Farwell AP, Braverman LE. Thyroiditis. *N Engl J Med*. 2003;348:2646-2655.
- Anderson L, Middleton WD, Teefey SA, Reading CC, Langer JE, Desser T, Szabunio MM, Mandel SJ, Hildebolt CF, Cronan JJ. Hashimoto thyroiditis: Part 2, sonographic analysis of benign and malignant nodules in patients with diffuse Hashimoto thyroiditis. *AJR Am J Roentgenol*. 2010;195:216-222.
- El Jai A. Les cancers différenciés de la thyroïde a propos de 35 cas. 2009.
- Released I. IBM SPSS Statistics for Windows. 20. Armonk, NY: IBM Corp; 2013.
- Kim GR, Kim EK, Kim SJ, Ha EJ, Yoo J, Lee HS, Hong JH, Yoon JH, Moon HJ, Kwak JY. Evaluation of underlying lymphocytic thyroiditis with histogram analysis using grayscale ultrasound images. *J Ultrasound Med*. 2016;35:519-526.
- Engkakul P, Mahachoklertwattana P, Poomthavorn P. Eponym: de Quervain thyroiditis. *Eur J Pediatr*. 2011;170:427-431.