



Diagnostic Evaluation and Characterization of Von Hippel-Lindau (VHL) Syndrome by Functional Imaging (^{68}Ga -DOTANOC, ^{99}mTc -HYNIC-TOC, and ^{131}I -MIBG)

Von Hippel-Lindau (VHL) Sendromunun Foksiyonel Görüntüleme (^{68}Ga -DOTANOC, ^{99}mTc -HYNIC-TOC ve ^{131}I -MIBG) ile Tanısal Açidan Değerlendirilmesi ve Nitelendirilmesi

Mohd Ashraf Ganie, Alpesh Goyal, Shyam Kishore, Ramkumar S, Chandan J. Das*, P. N. Dogra**, C. S. Bal***

Department of Endocrinology and Metabolism, All India Institute of Medical Sciences, New Delhi, India

*Department of Radiodiagnosis, All India Institute of Medical Sciences, New Delhi, India

**Department of Urology, All India Institute of Medical Sciences, New Delhi, India

***Department of Nuclear Medicine, All India Institute of Medical Sciences, New Delhi, India

Abstract

Von Hippel-Lindau syndrome, an autosomal dominant genetic disorder with high penetrance, is a rare genetic cause of pheochromocytoma and various other tumors, such as hemangioblastomas of retina and cerebellum, renal cell carcinoma, islet cell tumors, endolymphatic sac tumors, etc. Conventionally, Von Hippel-Lindau is diagnosed with the help of biochemical and structural imaging techniques, such as magnetic resonance imaging and computed tomography scans. However, the recent advent of the functional imaging techniques, such as meta-iodo-benzylguanidine, has significantly added to the armamentarium available for the diagnosis as well as localization of these tumors.

In this report, we describe a case of a 22-year-old male with VHL syndrome, where functional ^{68}Ga -DOTANOC PET/CT, ^{99}mTc -HYNIC-TOC SPECT/CT, and ^{131}I -MIBG SPECT/CT aided in the diagnostic evaluation of this disease. This patient presented with bilateral pheochromocytoma, retinal angioma, cerebellar hemangioblastoma, pancreatic neuroendocrine tumor, and pancreatic cysts. This case highlights the emerging role of functional imaging as an adjuvant to conventional tools in the diagnostic evaluations of diseases, an area that has not been addressed to date.

Keywords: VHL syndrome; pheochromocytoma; retinal angioma; cerebellar hemangioblastoma; pancreatic neuroendocrine tumor; ^{68}Ga -DOTANOC; ^{99}mTc -HYNIC-TOC; ^{131}I -MIBG, functional imaging

Özet

Yüksek penetranslı otozomal dominant genetik bir bozukluk olan Von Hippel-Lindau sendromu, feokromasitoma ve retinal ve serebellar hemanjioblastomlar, renal hücreli karsinom, adacık hücreli tümör, endolenfatik kese tümörleri gibi diğer birçok tümörün nadir genetik bir nedenidir. Konvansiyonel olarak, Von Hippel-Lindau tanısı manyetik rezonans görüntüleme ve bilgisayarlı tomografi taramaları gibi biyokimyasal ve yapısal görüntüleme teknikleri yardımı ile konmaktadır. Ancak, meta-iyodo-benzilguanidin gibi yakın zamanda kullanıma giren fonksiyonel görüntüleme teknikleri bu tümörlerin tanısı ve lokalizasyonlarının belirlenmesi için kullanılan tedavi gereçleri açısından önemli katkı sağlamıştır.

Bu vaka sunumunda, Von Hippel-Lindau sendromu olan ve hastalığın tanısal değerlendirilmesinde fonksiyonel ^{68}Ga -DOTANOC PET/CT, ^{99}mTc -HYNIC-TOC SPECT/CT ve ^{131}I -MIBG SPECT/CT kullanılan 22 yaşındaki bir erkek hasta tartışılmıştır. Hastamız iki taraflı feokromasitoma, retinal anjiyoma, serebellar hemanjiyoblastoma, pankreatik nöroendokrin tümör ve pankreatik kistler ile başvurdu. Biz, fonksiyonel görüntülemenin şimdiye kadar değinilmemiş bir alan olan hastalıkların tanısında geleneksel yöntemleri destekleyici yeni rolünü bu vaka üzerinden vurguladık.

Anahtar kelimeler: VHL sendromu; feokromasitoma; retinal anjiyoma; serebellar hemanjiyoblastoma; pankreatik nöroendokrin tümör; ^{68}Ga -DOTANOC; ^{99}mTc -HYNIC-TOC; ^{131}I -MIBG; fonksiyonel görüntüleme

Address for Correspondence: Mohd Ashraf Ganie, Endocrinology and Metabolism All India Institute of Medical Sciences, New Delhi, India

Phone: +91-11-26593968 **E-mail:** ashrafendo@gmail.com **Received:** 30/06/2016 **Accepted:** 08/01/2017

©Copyright 2018 by Turkish Journal of Endocrinology and Metabolism Association
Turkish Journal of Endocrinology and Metabolism published by Türkiye Klinikleri

Introduction

Von Hippel-Lindau (VHL) syndrome is an autosomal dominant genetic disorder with high penetrance (1, 2). A mutation in the tumor suppressor gene present on the short arm of chromosome 3 leads to the development of benign as well as malignant tumors, affecting multiple organ systems (1, 2). Various tumors that are associated with this syndrome are hemangioblastomas of the retina (retinal angioma), cerebellum, and spine, renal cell carcinoma (clear cell type), pheochromocytoma, islet cell tumors of the pancreas, endolymphatic sac tumors, cysts of kidney and pancreas, and cystadenoma in the epididymis and the broad ligament.

Case Report

A 22-year-old non-diabetic male presented with a six-month history of paroxysmal attacks of a headache, sweating, palpitation, weakness, postural dizziness, and about 10 kg weight loss. There was no history suggestive of hypoglycemia, thyrotoxicosis, recurrent fractures, renal calculi, neck swelling, abdominal or body lump, or any drug intake. Family history was unremarkable, except for the history of a certain unknown malignancy of chest in father. The patient also complained of the sudden onset of a painless, permanent visual loss in the left eye, which occurred two months earlier.

Clinical examination of the young male revealed a lean built (BMI= 15.6 kg/m²), with a pulse rate of 77 min⁻¹, supine BP of 186/110 mm of Hg, and standing BP of 64/40 mm of Hg. There was no perception of light in the left eye and its fundus examination revealed a retinal angioma along

with total retinal detachment, while the visual acuity and the fundus examination of the right eye were normal. There was no goiter, acanthosis nigricans, mucosal neuromas, café au lait spots, neurofibromas, or any Cushingoid features. Neurological examination, including the cerebellar examination, was unremarkable. Systemic examination, which included the cardiac, pulmonary, and abdominal examinations, was normal.

Investigative workup, including the blood counts, electrolytes, urinalysis, plasma glucose, glycated hemoglobin, renal and liver functions, were unremarkable. Other hormonal investigations included normal fasting plasma insulin (6.52; N 2.6-24.9 mIU/mL), serum T4 (7.66; N 5.1-14.1 mcg/dL), serum TSH (1.73; N 0.27-4.2 mIU/mL), serum morning cortisol (13.86; N 6.2-19.4 µg/dL), and plasma ACTH (9.43; N 7.2-63.3 pg/mL). The 24-hour urinary noradrenaline levels were elevated (275.0; N up to 90.0 mcg/day), with normal urinary adrenaline (4.0; N <30.0 mcg/day) and VMA (11.2; N <15.0 mg/day) levels. The fundus fluorescein angiography revealed a retinal angioma, along with retinal detachment (Figure 1). CECT (Figure 2a) and CEMRI of the abdomen (Figure 2b) revealed bilateral adrenal masses and a pancreatic mass lesion. MRI of the spine and cranium revealed a cerebellar lesion (Figure 2c). Chest roentgenography, electrocardiography, and echocardiogram were all normal (left ventricular ejection fraction= 60%). Audiometry (for endolymphatic tumors), USG of the neck (for medullary thyroid carcinoma), and Ultrasound of the scrotum (for epididymal cysts) were unremarkable.

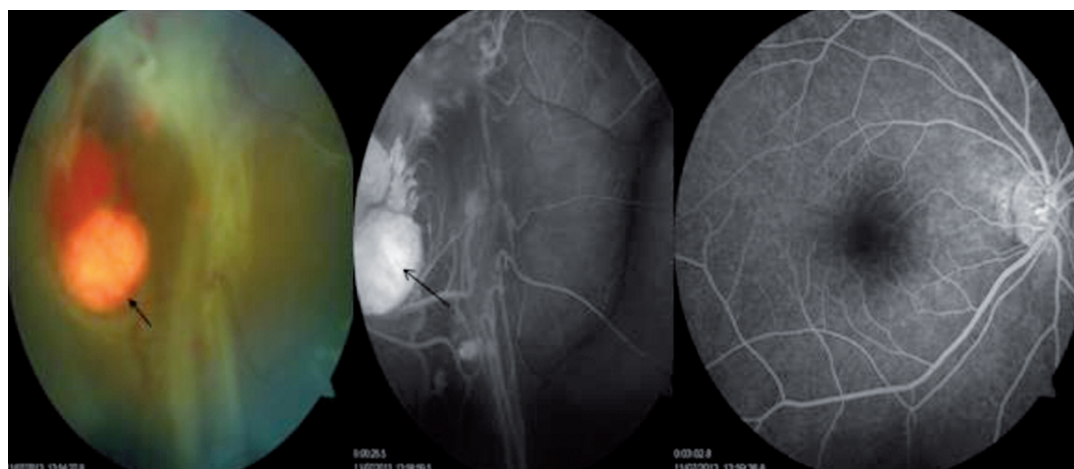


Figure 1: A fundus fluorescein angiographic image showing retinal angioma with retinal detachment.

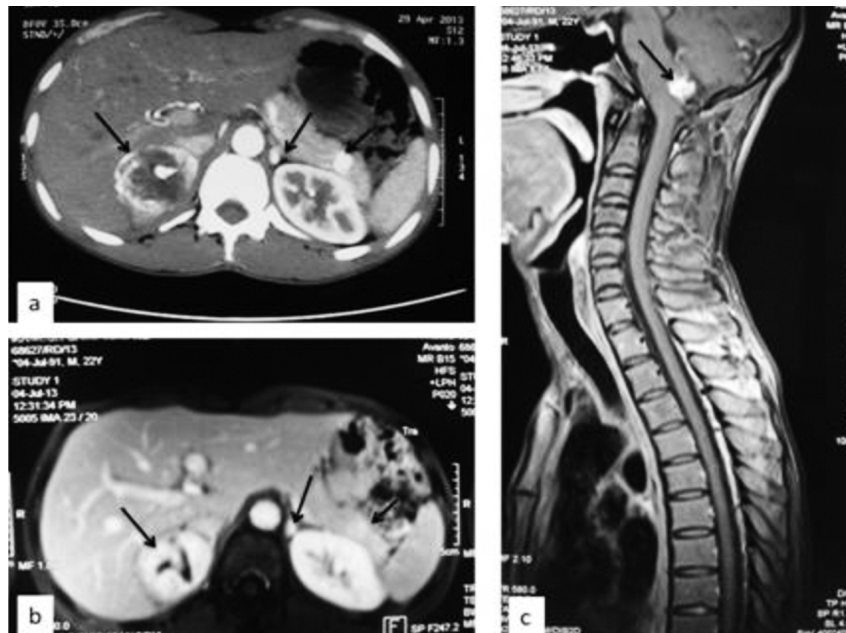


Figure 2: Contrast-enhanced CT in arterial phase **(a)** and post gadolinium T1 MRI **(b)** axial images showing an enhanced necrotic mass with the areas of calcification (long arrow) in the right suprarenal region. The note is made of the small enhancing lesion in the left suprarenal region (long arrow) as well as in the pancreatic tail (short arrow). Post gadolinium T1 MRI **(c)** in sagittal plane showing contrast-enhanced mass posterior to the pons.

^{131}I -MIBG along with SPECT/CT scan revealed bilateral MIBG-concentrating lesions, indicating bilateral pheochromocytoma, with greater uptake on the right side (Figure 3a-c). ^{68}Ga llium DOTANOC scan revealed uptake in the cerebellum, suggesting cerebellar hemangioblastoma (Figure 3d). $^{99\text{m}}\text{Tc}$ -HYNIC-TOC (Figure 3e) revealed a somatostatin receptor-expressing tumor in the tail region of the pancreas, which was suggestive of a neuroendocrine tumor, and it also revealed partially-calcified centrally-necrotic right-sided adrenal mass lesions (pheochromocytoma).

In this patient with components such as retinal angioma, bilateral pheochromocytoma, pancreatic neuroendocrine tumor, and cerebellar hemangioblastoma, a diagnosis of VHL syndrome was entertained. The patient was managed with a standard preoperative care procedure for pheochromocytoma and was then subjected to an open laparotomy in a joint approach by the urology and surgical gastroenterology teams. Intraoperative ultrasonography was performed in order to confirm the pancreatic lesions; three lesions were revealed in the ultrasonogram (one in the head region of the pancreas and two in the tail region of the pancreas). The operative proce-

dures included bilateral adrenalectomy, enucleation of the lesion in the head of the pancreas, and distal pancreatectomy for the other two lesions in the tail region of the pancreas. His post-operative period was uneventful. Two months later, he underwent the excision of the cerebellar hemangioblastoma. Postoperatively, the patient remained normotensive and without any neurodeficit, on a glucocorticoid and mineralocorticoid replacement therapy.

Discussion

VHL is usually present as a syndromic complex, characterized by retinal angiomas, hemangioblastoma of central as well as peripheral nervous system, along with cystic lesions in the viscera. The VHL syndrome is a rare genetic cause of pheochromocytoma, which occurs in one among 36,000 people, with >90% penetrance by the age of 65 years (3).

Most of the cases of pheochromocytomas are sporadic, and a familial association is found in up to 25% of the cases. The familial association occurs commonly with neurofibromatosis type 1, multiple endocrine neoplasia type 2, VHL syndrome, and paraganglioma syndrome. The VHL gene is a tumor suppressor gene that regulates the activity

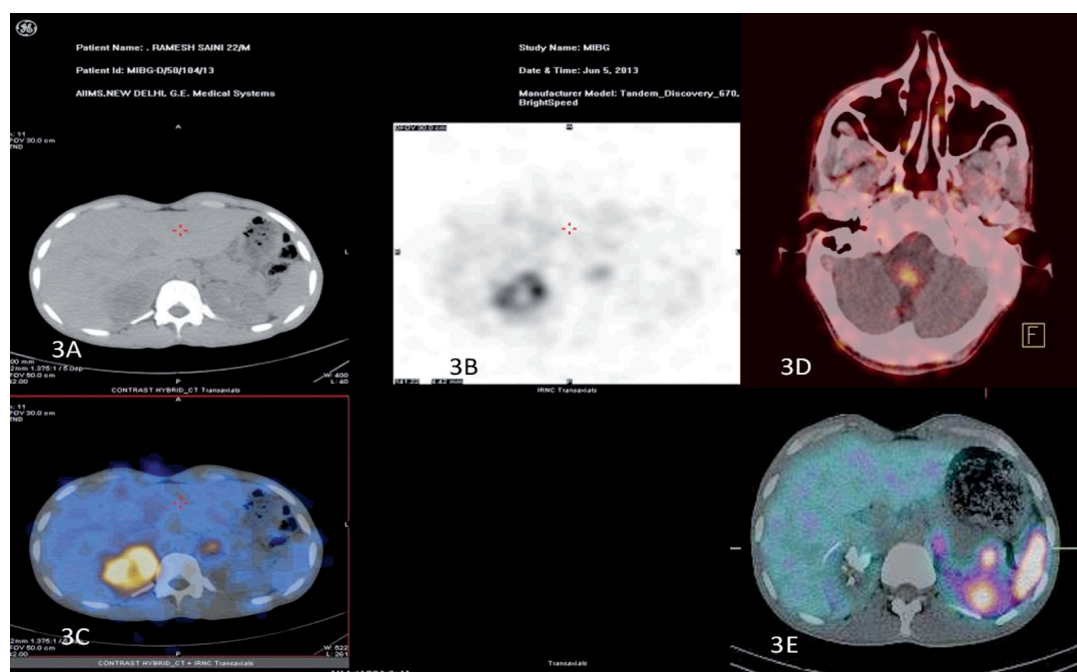


Figure 3: I-131 MIBG SPECT-CT showing B/L MIBG concentrating lesion in bilateral adrenal gland (R>L) s/o pheochromocytoma (right >left with necrosis on the right side), Ga-DOTANOC shows uptake in cerebellum s/o cerebellar hemangioblastoma, 99m Tc-HYNITOC shows somatostatin receptor expressing tumor in the tail of pancreas s/o NET as well as a partially calcified centrally necrotic right-sided adrenal mass lesion.

of hypoxia-inducible factor (HIF)-1 α , which is involved either in the upregulation of an angiogenic factor or in the downregulation of an inhibitor of angiogenesis. Approximately 80% of the individuals with the VHL disease have a positive family history, and only 20% of the cases develop as a result of *de novo* mutation. VHL have been classified into two categories based on the absence (type 1) or presence (type 2) of pheochromocytoma, with further sub-classification of the type 2 VHL into 2A (hemangioblastoma and pheochromocytoma), 2B (hemangioblastoma, renal cell carcinoma, pheochromocytoma, and pancreatic cyst or tumor), and 2C (only pheochromocytoma) categories.

The clinical diagnosis of the VHL disease is established in a patient when there is the presence of at least one typical VHL tumor along with a positive family history, or the presence of hemangioblastoma along with one other tumor when the family history is negative. The typical VHL tumors are retinal, spinal, and cerebellar hemangioblastomas; renal cell carcinoma; pheochromocytomas; endolymphatic sac tumors; and multiple pancreatic cysts. Renal and epididymal cysts occur very frequently in the general population as well; therefore, their presence as

a sole manifestation is not a reliable indicator of the VHL disease. VHL disease accounts for about 50% of the patients with apparently sporadic familial pheochromocytomas. Pheochromocytomas are the hallmark of VHL type 2. In this study, the presence of bilateral pheochromocytoma, retinal angioma, cerebellar hemangioblastoma, pancreatic cyst, and pancreatic neuroendocrine tumor in the patient indicated the presence of the VHL type 2a syndromic complex. The pheochromocytomas associated with the VHL syndrome exhibit more of a noradrenergic pattern, rather than the adrenergic pattern, of the total catecholamines content. Our patient also exhibited a predominant noradrenergic pattern in the 24-hour urinary catecholamines assay.

The incidental presence of the pancreatic cysts prompted us to suspect VHL syndrome in this patient, and an MRI of brain and spine was performed later in order to search for hemangioblastoma. The most common site for the presence of intracranial hemangioblastoma is cerebellum (37%), followed by spinal cord and brain stem. Our patient had a cerebellar hemangioblastoma (Figure 2c) and a retinal angioma. Retinal angiomas develop in more than one-half of the patients with the VHL syndrome. Most of

these lesions develop in the second or third decade of patient's life. The patients may also experience a painless loss of vision or certain visual field defects. Exudation or hemorrhage from the hemangioma may lead to macular edema or retinal detachment. Our patient had total retinal detachment, secondary to the left-sided retinal angiomas. Renal cell carcinoma, which is the leading cause of death in the patients with the VHL syndrome, was not present in our patient. In consideration of the raised urinary catecholamine levels and suspected VHL syndrome, functional imaging with ^{68}Ga -DOTANOC, $^{99\text{m}}\text{Tc}$ -HYNIC-TOC, and ^{131}I -MIBG was performed. In our patient, the CT scan initially revealed a left-sided adrenal lesion, and the bilateral pheochromocytoma was confirmed later with the ^{131}I -MIBG imaging. ^{68}Ga -DOTANOC and $^{99\text{m}}\text{Tc}$ -HYNIC-TOC were a part of our workup for the evaluation of the pancreatic neuroendocrine tumor. Both the scans revealed the presence of a pancreatic neuroendocrine tumor. The use of functional imaging in the diagnostic evaluation of the VHL lesions has not been reported previously. As a result of the multi-organ involvement and the complex nature of the VHL lesions, their treatment requires a multidisciplinary approach.

Our patient required surgical intervention by three surgical specialties: a urologist for the bilateral pheochromocytoma, a neurosurgeon for the hemangioblastoma, and gastrointestinal surgeon for the pancreatic neuroendocrine tumor. Since the size of the adrenal lesion was small, laparoscopic removal of the bilateral pheochromocytoma was planned on a priority basis. Surgical management of the pancreatic neuroendocrine tumor in the VHL syndrome is controversial. The VHL patients at a lower metastatic risk associated with the pancreatic NET should be spared for the hazards of an operative resection; unlike the patients with sporadic non-functioning NET without the VHL disease, in such as case, surgical resection is generally recommended. Libutti & colleagues (10) recommended the following criteria for the resection of pancreatic tumors: no evidence of metastatic disease; tumor size greater than 3 cm in the body or the tail region, or greater than 2 cm in the head region of the pancreas; or the patient undergoing laparotomy for other lesions. Blansfield et al. (11) proposed the following three criteria to predict the metastatic disease associated with the pancreatic NET in the patients with the VHL disease: tumor size greater than or equal to 3 cm; the presence of a muta-

tion in exon 3; and a tumor doubling time of less than 500 days. If the second or the third criterion is fulfilled, the patient should be considered for surgical management because of a greater likelihood of future malignancy developing from the pancreatic NET.

The blood pressure of our patient was controlled with adequate alpha and beta blockade. We consulted both urologists and surgical gastroenterologists, and planned for an initial bilateral adrenalectomy through laparotomy that would be performed by the urology team; and then if the patient remained stable, we would proceed with the resection of the pancreatic tumors which would be performed by the surgical gastroenterologist within the same setting. The patient underwent laparotomy and the bilateral adrenalectomy was performed for the pheochromocytoma. The intraoperative ultrasonography was performed in order to confirm the pancreatic lesions; the ultrasonogram revealed three lesions (one in the head region of the pancreas and two in the tail region of the pancreas). The patient, therefore, underwent enucleation of the lesion in the head region of the pancreas, and distal pancreatectomy was performed for the removal of the other two lesions in the tail region of the pancreas. His postoperative period was uneventful. He required periodic follow-up with the neurosurgeon and the urologist for the hemangioblastoma and renal cell carcinoma, respectively. Although the renal cell tumor was not observed in this patient, this tumor is the most common cause of death in the patients with the VHL syndrome, and therefore, periodic imaging is recommended, preferably with the MRI of the abdomen.

Conclusion

Here, we have described a typical syndromic complex of VHL type 2a in a young male with lesions in the cerebellum, retina, bilateral adrenals, and pancreas. VHL should be suspected in patients with bilateral pheochromocytoma, especially if there is a family history, occurrence at a young age, or if there are associated lesions of pancreas, kidneys or the central nervous system. The treatment of VHL requires a multidisciplinary approach, involving various specialties-endocrinology, urology, surgical gastroenterology, radiology, nuclear medicine, and neurosurgery. The role of functional imaging in the characterization of the lesions associated with the VHL syndrome has been addressed for the first time in

this report. We recommend the addition of functional imaging in the list of comprehensive surveillance of the VHL-related tumors.

Competing Interests: None.

Source of Finance: During this study, no financial or spiritual support was received neither from any pharmaceutical company that has a direct connection with the research subject, nor from a company that provides or produces medical instruments and materials which may negatively affect the evaluation process of this study.

Conflict of Interest: No conflicts of interest between the authors and/or family members of the scientific and medical committee members or members of the potential conflicts of interest, counseling, expertise, working conditions, share holding and similar situations in any firm.

Author Contributions

Concept: Mohd Ashraf Ganie; Design: Alpesh Goyal; Data Collection or Processing: Shyam Kishore; Analysis or Interpretation: Mohd Ashraf Ganie, C.S.Bal, P.N.Dogra, Alpesh Goyal, Shyam Kishore; Literature Search: Alpesh Goyal, Shyam Kishore; Writing: Alpesh Goyal/Shyam Kishore.

References

1. Latif F, Tory K, Gnarr J, Yao M, Duh FM, Orcutt ML, Stackhouse T, Kuzmin I, Modi W, Geil L. Identification of the von Hippel-Lindau disease tumour suppressor gene. *Science*. 1993;260:1317-1320.
2. Maher ER, Iselius L, Yates JR, Littler M, Benjamin C, Harris R, Sampson J, Williams A, Ferguson-Smith MA, Morton N. Von Hippel-Lindau disease: a genetic study. *J Med Genet*. 1991;28:443-447.
3. Maher ER, Kaelin WG Jr. Von Hippel-Lindau disease. *Medicine (Baltimore)*. 1997;76:381-391.
4. Melmon KL, Rosen SW. Lindau's disease. Review of the literature and study of a large kindred. *Am J Med*. 1964;36:595-617.
5. Neumann HP, Wiestler OD. Clustering of features of von Hippel-Lindau syndrome: evidence for a complex genetic locus. *Lancet*. 1991;337:1052-1054.
6. Maher ER, Yates JR, Harries R, Benjamin C, Harris R, Moore AT, Ferguson-Smith MA. Clinical features and natural history of von Hippel-Lindau disease. *Q J Med*. 1990;77:1151-1163.
7. Richard S, Campello C, Taillandier L, Parker F, Resche F. Hemangioblastoma of the central nervous system in von Hippel-Lindau disease. French VHL Study Group. *J Intern Med*. 1998;243:547-553.
8. Dollfus H, Massin P, Taupin P, Nemeth C, Amara S, Giraud S, Bérout C, Dureau P, Gaudric A, Landais P, Richard S. Retinal hemangioblastoma in von Hippel-Lindau disease: a clinical and molecular study. *Invest Ophthalmol Vis Sci*. 2002;43:3067-3074.
9. Tamura K, Nishimori I, Ito T, Yamasaki I, Igarashi H, Shuin T. Diagnosis and management of pancreatic neuroendocrine tumor in von Hippel-Lindau disease. *World J Gastroenterol*. 2010;16:4515-4518.
10. Libutti SK, Choyke PL, Alexander HR, Glenn G, Bartlett DL, Zbar B, Lubensky I, McKee SA, Maher ER, Linehan WM, Walther MM. Clinical and genetic analysis of patients with pancreatic neuroendocrine tumours associated with von Hippel-Lindau disease. *Surgery*. 2000;128:1022-1028.
11. Blansfield JA, Choyke L, Morita SY, Choyke PL, Pingpank JF, Alexander HR, Seidel G, Shutack Y, Yuldasheva N, Eugeni M, Bartlett DL, Glenn GM, Middleton L, Linehan WM, Libutti SK. Clinical, genetic and radiographic analysis of 108 patients with von Hippel-Lindau disease (VHL) manifested by pancreatic neuroendocrine neoplasms (PNETs). *Surgery*. 2007;142:814-818.